

Calcification of the Intervertebral Discs and Curvature of the Radius and Ulna: A Radiographic Survey of Finnish Miniature Dachshunds

By A. Lappalainen, M. Norrgård, K. Alm, M. Snellman and O. Laitinen

Faculty of Veterinary Medicine, Department of Clinical Veterinary Sciences, University of Helsinki, Finland.

Lappalainen A, Norrgård M, Alm K, Snellman M, Laitinen O: Calcification of the intervertebral discs and curvature of the radius and ulna: A radiographic survey of Finnish miniature dachshunds. Acta vet. scand. 2001, 42, 229-236. – The vertebral column of 124 randomly selected miniature dachshunds, representing 4.5% of the population registered by the Finnish Kennel Club during the years 1988 to 1996, were radiographed. The front legs were also radiographed in order to evaluate the curvature of the radius and ulna. Calcified discs were found in 75.9% of the longhaired miniature dachshunds and in 86.7% of the wirehaired ones. The occurrence of signs associated with IDD was 16.5% in longhaired and 15.6% in wirehaired miniature dachshunds. The occurrence of signs of IDD in dogs with calcified discs was 20.0% and 17.9% in longhaired and wirehaired miniature dachshunds, respectively. In dogs without calcifications only one dog showed signs of IDD. The curvature of the radius and the ulna did not differ between the dogs with signs of IDD and the healthy ones, or between the dogs with and without intervertebral calcifications. Our results indicate that radiographic eradication based on the presence of intervertebral calcifications is not suitable for breeding purposes for the Finnish miniature dachshund population because the percentage of dogs without calcifications is small.

disease; vertebral column; radius-ulna; radiology; dog; survey; chondrodystrophy; breeding.

Introduction

Intervertebral disc disease (IDD) is a common cause of back pain and neurological deficits in the dog. It most commonly affects dachshunds and other chondrodystrophic breeds with an occurrence of 19% in dachshunds (Ball 1982). Chondrodystrophic breeds are genetically predisposed to an early intervertebral disc degeneration (Ghosh 1975); most of the discs contain a calcified fibrocartilagenous nucleus pulposus by the first year of age (Hansen 1952). It has been shown that IDD (Havranek-Balzaretti 1980, Ball 1982) and intervertebral calcifications (Havranek-Balzaretti 1980) are hereditary in dachshunds and dogs with calcified discs are

at greater risk to develop clinical signs of IDD than dogs without calcifications (Havranek-Balzaretti 1980, Stigen 1996). Therefore radiographic screening of the spines might be useful in breeding programs. It has also been postulated that straight-legged dachshunds would be less susceptible to IDD than crooked-legged ones (Hansen 1964).

There are, however, no studies to confirm this hypothesis. If this was the case, radiographic screening of the radius and ulna might be of value in reducing the occurrence of IDD in dachshunds.

Previous radiographic studies have focused on

standard size dachshunds (*Havranek-Balzaretti* 1980, *Stigen* 1991, 1993, 1996). It seems that IDD is particularly common in Finnish miniature dachshunds. The objective of this radiographic study was to evaluate the occurrence of calcified intervertebral discs in Finnish miniature dachshunds and to compare the relationship between the curvature of the radius and ulna with the degree of disc calcification.

Materials and methods

Longhaired and wirehaired miniature dachshunds (chest circumference less than 35 cm) were selected from the Finnish Kennel Club's register based on their regional as well as familiar backgrounds. A systematic selection method was used to ensure that the sample of dogs was spread more evenly over the population than a simple random sample. Furthermore, by appropriate ordering of units, a systematic sample also provides a stratification effect with equal sampling fractions. As a result a self weighing sample gives the possibility to study differences between groups according to their sires, and to get offspring from as many sires as possible without explicit and detailed stratification. The main disadvantage of this method is the accuracy of the estimates, which can only be approximated. Based on this the dogs were sorted according to their sires and to the owners' postal codes. Thus we had reason to expect that units which were close together would be more alike than those further apart. Every tenth dog (altogether 221 dogs) was selected from the list and a questionnaire was sent to those owners whose addresses were available, accounting for 8.1% of the total miniature dachshund population registered during 1988 to 1996. Each owner was asked if their dog had had any symptoms of IDD (unwillingness to jump or walk, unexplained pain or ataxia) and if it had been treated for it. Finally, the owner was requested to bring the dog to the Veterinary

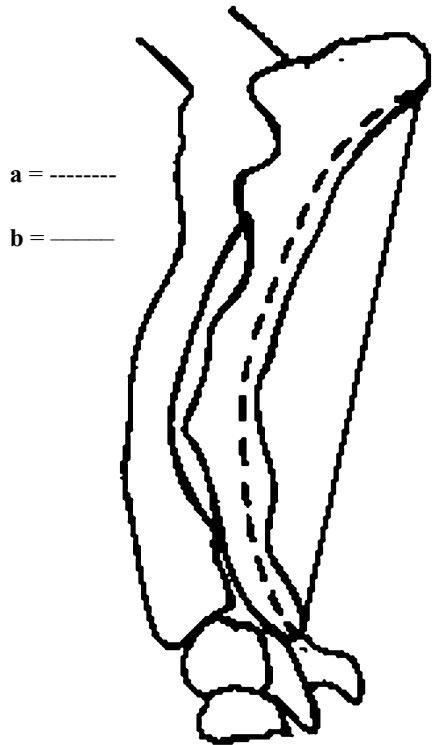


Figure 1. Curvature ratio defined as the length of a divided by the length of b.

Teaching Hospital of Helsinki University for a radiographic survey of the spine and front legs. For the radiographic examination the dogs were sedated with medetomidine (Domitor® 1 mg/ml) 20 µg/kg and butorphanol (Torbugesic® 10 mg/ml) 0.2 mg/kg intramuscularly (IM). Lateral radiographs were taken of the whole vertebral column including the cervical area and from the right radius and ulna. Three exposures using 20 × 40 cm film (T-MAT E Film, Kodak) were taken of each vertebral column. The x-ray machines used were Bennett HFQ Thousand Series and Siemens Gigantos 1012 MP. Both had a mobile grid. The dogs were positioned according to recommendations by *Morgan et al.*

Table 1. Age and weight with mean and standard deviation (SD) of longhaired and wirehaired miniature dachshunds.

	Longhaired miniature dachshund			Wirehaired miniature dachshund		
	Male	Female	Total	Male	Female	Total
Age (year)	1-9	1-9	1-9	1-8	1-9	1-9
(mean, SD)	(4, 2.3)	(4, 2.4)	(4, 2.3)	(4, 1.9)	(4, 2.3)	(4, 2.1)
Weight (kg)	3.2-11.0	2.7-10.2	2.7-11.0	4.0-8.9	3.5-8.6	3.5-8.9
(mean, SD)	(6.5, 1.6)	(5.4, 1.3)	(5.8, 1.5)	(6.4, 1.3)	(5.8-1.3)	(6.0, 1.3)

(1977). The front leg was positioned so that the distal epicondyles of humerus superimposed each other and the whole elbow joint space could be seen even and clearly. After taking the radiographs the dogs were given atipamezole (Antisedan® 5 mg/ml) 0.1 mg/kg IM to reverse the sedation.

The authors evaluated the radiographs together. The number of calcified discs was calculated and their location in the vertebral column was recorded. Every visible calcification was included, also very small and opaque ones. The measurements used in evaluating the curvature of the radius and ulna are shown in Fig. 1, where "a" describes the curved line along ulna between distal epiphyseal line of olecranon and distal end of styloideal process, and "b" describes the straight line between these points. The ratio between "a" and "b" was used as a value for the curvature.

Standard errors were calculated by estimators designed to be used with simple random sampling. The Chi square test was used to test differences between dogs with calcifications and dogs with IDD in relation to sex, age groups and groups of offspring. A Kruskal-Wallis analysis of variance was used to test for differences in the median number of calcifications between age groups and for differences in the median of the curvature ratio between groups formed according to the health and calcification status of the dogs. The Mann-Whitney test was

used when testing for differences in median numbers of calcifications between sexes and groups of offspring. The results are expressed as percentages (\pm standard error) and as means (standard deviation) or as medians.

Results

In all, 174 owners (79%) returned the questionnaire. Radiographs were taken of 124 dachshunds (79 longhaired and 45 wirehaired) representing 4.5% of the miniature dachshund population registered by the Finnish Kennel Club during the years 1988 to 1996. The longhaired dogs were from 64 sires and 73 dams and the wirehaired from 32 sires and 38 dams. Most of the sires had only one offspring included in this study (Fig. 2). In both breeds there were 65% females and 35% males. The ages and weights of the dogs are presented in Table 1.

According to the owners 20 out of 114 (17.5% \pm 3.6%) longhaired miniature dachshunds and 12 out of 60 wirehaired miniature dachshunds (20.0% \pm 5.2%) had showed clinical signs of IDD (ataxia or back pain according to owners or diagnosed by a veterinarian in 28 dogs). At least 2 dogs had been euthanized because of IDD before the radiographic study. The occurrence of signs indicative of IDD was 16.5% (\pm 4.2%) (13/79) in longhaired and 15.6% (\pm 5.4%) (7/45) in wirehaired miniature dachshunds, respectively (Fig. 3). In the dogs with calcified discs the occurrence was 20.0% \pm

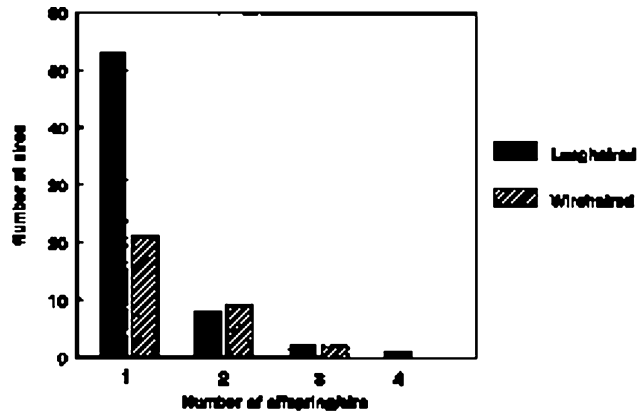


Fig. 2. Number of offspring/sire included in the study.

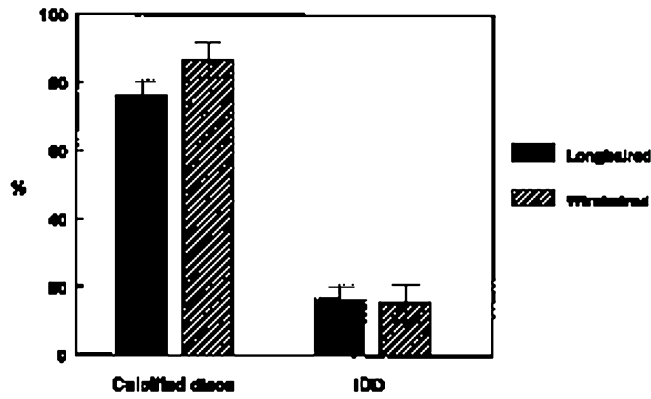


Fig. 3. Percentage (\pm SE) of dogs with calcifications and dogs with IDD.

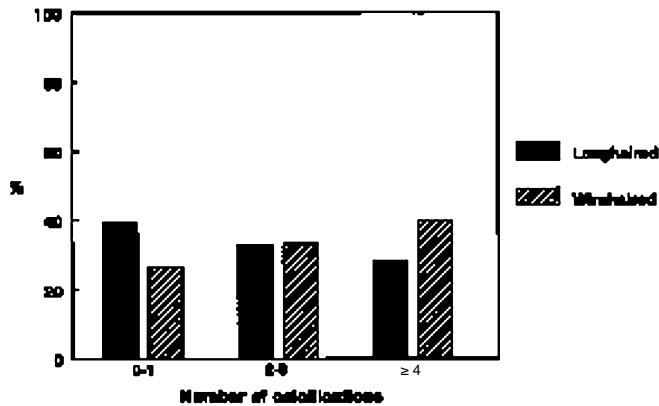


Fig. 4. Percentage of dogs with different numbers of calcifications.

5.2% (12/60 dogs) and $17.9\% \pm 6.1\%$ (7/39 dogs) in longhaired and wirehaired dachshunds, respectively. One out of 25 dogs (4%) without calcifications had had clinical signs of IDD.

Calcified discs were found in 60 out of 79 ($75.9\% \pm 4.8\%$) of the longhaired miniature dachshunds and in 39 out of 45 ($86.7\% \pm 5.1\%$) of the wirehaired ones (Fig. 3). Calcifications were found in all intervertebral spaces that contain disc. In longhaired miniature dachshunds most of the calcifications were at spaces T10-T11 (9.5%) and T11-T12 (7.5%) and in wirehaired ones at spaces L2-L3 (11.8%) and T12-T13 (10.5%). Six dogs (4 longhaired and 2 wirehaired ones) had calcifications only in the cervical spine. In the longhaired miniature dachshunds the number of calcifications within a single dog varied from 0 to 13 (mean 2.5, SD 2.4, median 2.0). Of longhaired dogs 31 (39.2%) had none or one calcification, 26 dogs (32.9%) had 2 or 3 calcifications and 22 dogs (27.9%) had 4 or more calcifications (Fig. 4). In the wirehaired the number of calcifications varied from 0 to 11 (mean 3.4, SD 2.9, median 2.0). Of wirehaired ones 12 dogs (26.7%) had none or one calcification, 15 dogs (33.3%) had 2 or 3 calcifications and 18 dogs (40.0%) had 4 or more calcifications (Fig. 4). There was no statistically significant difference between longhaired and wirehaired miniature dachshunds in the percentage of dogs with calcifications or clinical signs of IDD, or in the number of calcifications within a single dog. The presence of calcification was not related to sex or age in either breed nor was the age related to the number of calcified discs. The median number of calcifications was 2.0 in 2-3 and 4-7-year-old dogs in both breeds. In 8-10-year-old dogs the median number was 2.0 in longhaired and 5.0 in wirehaired dogs.

The values for the radial curvature were as follows: In healthy dogs without calcifications the

median number of the ratio between "a" and "b" was 1.14 ("a/b" varied between 1.11 – 1.21, "a" varied between 6.3 – 8.8 cm, median was 7.4 cm and "b" varied between 5.5 – 7.5 cm, median was 6.5 cm). In healthy dogs with calcifications the median number of the ratio between "a" and "b" was 1.15 ("a/b" varied between 1.10 – 1.23, "a" varied between 6.7 – 8.7 cm, median was 7.8 cm and "b" varied between 5.8 – 7.7 cm, median was 6.6 cm). In diseased dogs with calcifications the median number of the ratio between "a" and "b" was 1.16 ("a/b" varied between 1.11 – 1.21, "a" varied between 7.0 – 8.5 cm, median was 7.7 cm and "b" varied between 5.8 – 7.5 cm, median was 6.6 cm). Only one dog had clinical signs of IDD without calcifications and it was excluded from the study. There was no statistical difference in the median radial curvature ratio between the 3 groups ($p = 0.5600$).

Discussion

The occurrence of intervertebral disc calcifications was 76% in longhaired miniature dachshunds and 87% in wirehaired ones. This is clearly higher than in previous studies where 40%-60% of the dachshunds had calcifications (Havranek-Balzaretti 1980, Stigen 1996, Morgan 1997). There can be several reasons for this: genetic factors are probably the most important ones. It has been shown that the occurrence of calcifications depends on coat type and the size of dog (Stigen 1991). In Stigen's survey calcifications were most common among miniature wirehaired (75.0%) and miniature longhaired (45.6%) dachshunds but only 9.1% of standard shorthaired dachshunds had calcifications. In previous studies (Havranek-Balzaretti 1980, Stigen 1991, 1996) the dogs were geographically from quite limited areas and this might have influenced the results. We avoided this by sorting the dogs from the Finnish Kennel Club's register after sires and according to

the postal codes. In this way we could be sure that an offspring of a certain sire or dogs from a certain area were not over-represented. The dogs were from 96 different sires and 111 dams, and the percentage of calcifications in the offspring of dogs which had more than one offspring included in the study was similar to that of the whole group, indicating successful sampling.

Havranek-Balzaretti (1980) has postulated that dogs with only one calcification might be at a lesser risk of getting clinical signs of IDD. Similarly it can also be postulated that dogs with many calcifications are at a greater risk of getting clinical IDD than dogs with only few calcifications. In our material the proportion of dogs with many calcifications (4 or more) was quite high and even higher (40%) in wirehaired than longhaired (28%) dogs. The difference between breeds was, however, not statistically significant. In our study the age of the dog was not related to the number of the calcifications unlike in the study of *Stigen* (1995) where older dogs had more calcifications than younger ones. We found, like *Stigen* (1991), that there was no difference in the occurrence of calcifications between sexes.

The number of calcified discs and their distribution in a single dog were the same as in previous studies (*Stigen* 1991, 1996). According to *Havranek-Balzaretti* (1980) calcifications are not present only in the cervical spine. In our study, however, this was the case in 6 dogs (4.8%). Calcifications can disappear (*Stigen* 1996) and this might explain the difference in the results. Furthermore we also found it imperative to sedate the dogs for radiographs to assure the optimal positioning for detecting also the smallest calcifications unlike *Havranek-Balzaretti* (1980) and *Morgan* (1997) who did not sedate their dogs for radiographs. The occurrence of IDD in dogs with calcified discs varies in different studies. It is difficult to

make comparisons since the mean age differs in every study. According to a study of 100 dachshunds with a mean age of 7.4 years by *Havranek-Balzaretti* (1980), 79% of the dogs with calcified discs had signs of IDD. *Stigen* (1996) found that 23.9% of dogs under 6 years of age with calcifications had signs of spinal disease. The mean age of radiographed dogs in our study was only 4 years. Probably some of them will develop clinical signs of IDD later in their life since the peak incidence of IDD is between 4 and 6 years (*Gage* 1975, *Priester* 1976). This can explain the low incidence of clinical signs indicative of IDD in our material. Our results, like *Stigen's* (1991), suggest that there are other factors besides the disc calcification influencing the development of IDD. Athletic dogs may be less susceptible since adequate muscle mass has a protective function against IDD (*Hoerlain* 1979). *Verheijen & Bouw* (1982) emphasized the role of obesity and poor muscle condition as a predisposing factor. It seems highly probable that dogs without calcifications do seldom suffer from IDD. In previous studies dogs without calcifications had never (*Havranek-Balzaretti* 1980) or seldom (*Stigen* 1996) signs of IDD. In our study only 1 dog without calcifications had shown signs of IDD.

Chondrodystrophy is an anomaly in skeletal development, where there is a disturbance in endochondral ossification. Owing to a retarded and prematurely arrested ossifying process, chondrodystrophy results in disproportionately short and curved extremities. Early intervertebral disc degeneration accompanies this kind of dwarfism (*Hansen* 1952). *Hansen* (1964) has postulated that the curvature of the legs is proportional to the degree of the chondrodystrophy and by breeding straight-legged dachshunds the occurrence of IDD could be reduced. The differences in the curvature of the radius and ulna between individuals were very small and we

could not find any differences compared to incidence of calcified discs.

Conclusion

Based on our study the occurrence of intervertebral calcifications in longhaired and wire-haired miniature dachshunds is very high in Finland. Thus, radiographic eradication based on the presence of intervertebral calcifications is not suitable for breeding purposes in these dog populations. Breeding programs should be based on the health status of the dog and its close relatives. At the same time it would, however, be beneficial to examine as many dogs as possible and use those without calcifications for breeding. The dogs with very many calcifications should not be used. The whole spine including the cervical area should be radiographed under sedation. The radiographs of the radius and ulna are of no benefit in breeding programs.

Acknowledgements

The authors thank Mrs. Lea Suutari for assistance in selecting the dogs and Päivi Kallioniemi, DVM, Iris Rastas, DVM and Kaisa Wickström, DVM for radiographing some of the dogs. This work was done with the financial support of the Finnish Kennel Club.

References

- Ball MU, McGuire JA, Swaim SF, Hoerlain BF: Patterns of occurrence of disk disease among registered Dachshunds. *JAVMA* 1982, 180, 519-522.
- Gage ED: Incidence of clinical disc disease in the dog. *JAAHA* 1975, 11, 135-138.
- Ghosh P, Taylor TKF, Yarrow JM: Genetic factors in the maturation of the canine intervertebral disc. *Res. Vet. Sci.* 1975, 19, 304-311.
- Hansen H: A pathologic-anatomical study on disc degeneration in dog. *Acta Orthop. Scand., Suppl.* 11, 1952, 1-117.
- Hansen HJ: The body constitution of dogs and its importance for the occurrence of disease. *Nord. Vet. Med.* 1964, 16, 977-987.
- Havraneck-Balzaretti B: Beitrag zur Aetiologie der Dackellähme und Vorschlag zur züchterischen Selektion. (Etiology of the intervertebral disc disease in dachshunds and suggestions for breeding). *Veterinär-Medizinischen Fakultät der Universität Zürich, Thesis*, 1980.
- Hoerlain BF: Comparative disk disease: man and dog. *JAAHA* 1979, 16, 535-545.
- Priester WA: Canine intervertebral disease – occurrence by age, breed, and sex among 8 117 cases. *Theriogenology* 1976, 6, 293-303.
- Morgan JP, Silverman S, Zontine WJ: *Techniques of Veterinary Radiology*, The Printer, Davies, 1977.
- Morgan JP: Radiographic survey of intervertebral disc disease in dachshunds. Abstract, The 11th meeting of the International Veterinary Radiology Association (IVRA), Jerusalem, 1997.
- Stigen O: Calcification of intervertebral discs in the dachshund: a radiographic study of 115 dogs at 1 and 5 years of age. *Acta Vet. Scand.* 1996, 37, 229-237.
- Stigen O: Calcification of intervertebral discs in the dachshund: a radiographic study of 21 stud-dogs. *Acta Vet. Scand.* 1995, 36, 329-334.
- Stigen O, Christensen: Calcification of intervertebral discs in the dachshund: an estimation of heritability. *Acta Vet. Scand.* 1993, 34, 357-361.
- Stigen O: Calcification of intervertebral discs in the dachshund. A radiographic study of 327 young dogs. *Acta Vet. Scand.* 1991, 32, 197-203.
- Verheijen J, Bouw J: Canine intervertebral disc disease: a review of etiologic and predisposing factors. *Vet. Quart.* 1982, 4, 125-134.

Sammanfattning

Kalsifikation av intervertebrala diskar samt böjningen av radius och ulna: en röntgenologisk undersökning av finska dvärgtaxar.

Ryggkotpelaren hos 124 slumpvis utvalda dvärgtaxar, som representerar 4.5% av den registrerade populationen hos Finska Kennelklubben under åren 1988-1996, undersöktes med hjälp av röntgen. Även frambenen röntgades och böjningen av radius och ulna uppmättes. Förekalkade diskar konstaterades hos 75.9% av de undersökta långhåriga dvärgtaxarna och hos 86.7% av de strävåriga. Hos 16.5% av de långhåriga och 15.6% av de strävåriga dvärgtaxarna förekom symptom på intervertebral disksjukdom. Förekomsten disksjukdom hos hundar med förekalkningar i diskmassan var 20.0% samt 17.9% hos långhåriga respektive strävåriga dvärgtaxar. Av de hundar som inte hade förekalkningar var det bara en som visade symptom på intervertebral disksjukdom.

Böjningsgraden på radius och ulna skilde sig inte mellan hundar med symptom på disksjukdom och friska individer, eller mellan hundar med förkalkningar och sådana som saknade förkalkningar. Våra resultat indikerar att det inte är lämpligt, när det

gäller populationen dvärgtaxar i Finland, att utesluta individer från avel genom röntgenologisk påvisning av förkalkningar mellan kotkropparna, på grund av det förhållandevis låga antalet hundar utan förkalkningar.

(Received November 4, 2000; accepted November 22, 2000).

Reprints may be obtained from: A. Lappalainen, Department of Clinical Veterinary Sciences, Faculty of Veterinary Medicine, P. O. Box 57, FI-00014 University of Helsinki, Finland. E-mail: anu.k.lappalainen@helsinki.fi, tel: 358 9 19149686, fax: 358 9 19149670.