

## A Combination of Atrioventricular Block and Sinoatrial Block in a Horse

By A. Rezakhani, M. Godarzi, I. Tabatabaei Naeini

Department of Clinical Studies, School of Veterinary Medicine, Shiraz University, P.O. Box 1731, Shiraz 71345, Iran.

In the process of carrying out a routine check up examination on a group of horses of a riding school in Shiraz, a horse demonstrated frequent long pauses in heart rate of 33 beats per minute on auscultation. A base apex electrocardiogram (ECG) was recorded to determine the type of conduction disturbance. At the time of ECG recording, the animal was normal with no apparent sign of any body disorders and respiratory movement and temperature were within normal range. CBC and serum biochemical analysis carried out were within normal limits of our school reference values. The horse was given a light exercise and was examined immediately after exercise and 15 minutes thereafter. The heart rate immediately after the end of exercise was 65 bpm and slowed down to 35 bpm 15 minutes after exercise with no sign of heart block.

### ECG interpretation

The first two complexes of the ECG appeared to be conducted normally through the heart following initiation of the sinoatrial node (Fig.1); however, the P-R interval was variable and the third P wave was blocked at the A-V node. The mean P-P interval was about 1.80 second indicating a sinus rate of 33 beats per minute. Following the first blocked P-wave, there was a

long pause, which was slightly more than twice the previous P-P interval. There was no electrical activity during this pause indicating a concomitant sinoatrial block (SAB). The underlying rhythm was sinus arrhythmia as the P-P or R-R intervals were variable. There was also a single atrioventricular block (AVB) in the second trace. No single SAB without accompanying AVB was observed on the ECG.

### Discussion

The prevalence of cardiac arrhythmias among domestic animals is more common in the horse (McGuirk & Muir 1985) than in other species and the majority of these dysrhythmias are not clinically significant. Sinus arrhythmia, sinoatrial block, wandering pacemaker, first and second degree atrioventricular blocks are considered to be vagally mediated conduction disturbances and waxing and waning of the vagal nerve is believed to be the cause of these cardiac irregularities (Reef 1989). Of these cardiac dysrhythmias, second degree AVB is more common (Holmes 1990, Gabriel & Lekeux 1986). There are three types of AVB; that is, first degree AVB in which all impulses originating from the SA node conduct to the ventricle with longer than normal P-R interval (P-R > 0.50 sec.). Although this can be diagnosed

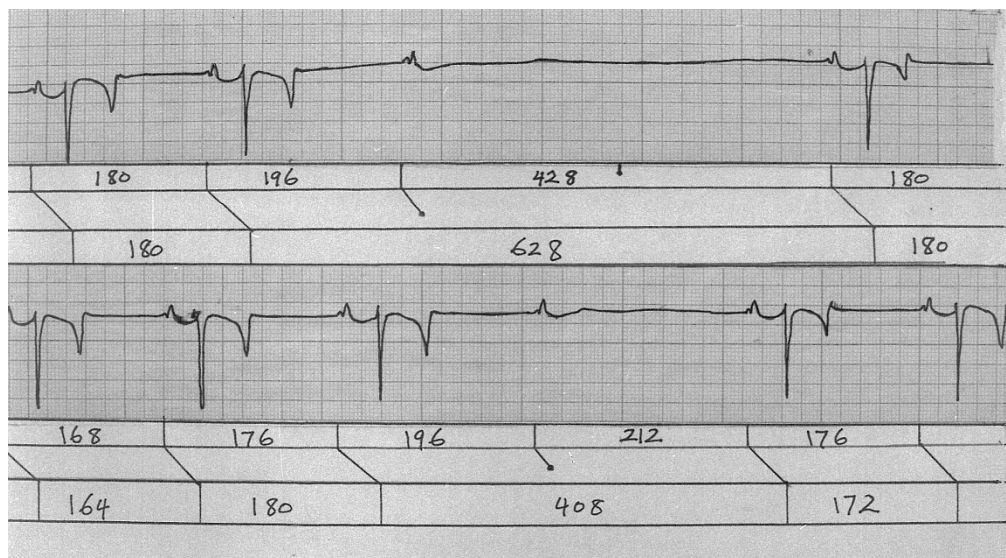


Figure 1. Base -apex electrocardiogram recorded from a horse with concomitant second degree atrioventricular and sinoatrial block. The underlying rhythm is a slight sinus arrhythmia. The pause between the first blocked P wave and the next P wave is slightly longer than 2 P-P intervals indicating SAB. Paper speed is 25mm per second and calibration 10 mm equal to 1 mV.

on auscultation, ECG is needed for confirmation. In second degree AVB, some of the P waves are not followed by the QRS complexes, therefore, there are more P waves than QRS complexes and during the missed beat the fourth heart sound can be heard. There are two types of second degree AVB. In type I, the P-R interval lengthens gradually until a P-wave is blocked but in type II the P-R intervals remain fixed. In third degree AVB, the electrical relationship of the atria and the ventricles are disrupted.

The prevalence of second degree AVB is around 15 to 40% in the equine population (Reef 1989, Holmes 1990). It has been considered functional provided that it disappears after light exercise (Holme 1990). It has been stated that training has effect on the autonomic nervous function (Ohmura et al. 2002) and vagally mediated cardiac dysrhythmias are more com-

mon in trained horses although AVB has also been reported in a 2.5 months thoroughbred foal (Matsui et al. 1988). There are also reports that cardiac lesions can be associated with AVB and SAB in the horse (Kiryu et al. 1977, Kiryu et al. 1985). The SAB occurs much less frequent than AVB in horses (Smetzer 1967). Although AVB and SAB may occur simultaneously on the ECG of a horse their association is very rare. A review of literature showed that only one case has been reported in a doctoral thesis (Smetzer 1967) therefore, this can be accepted as the first published case of a concomitant AVB and SAB in the horse. The horse was clinically normal and used for jumping so this type of conduction disturbance could be taken as a functional block. However, periodic checking of the cardiovascular system is recommended.

**References**

- Gabrie F, Lekeux P*: Etude des arythmias cardiaques chez 159 chevaux de selle Belges. *Ann. Med. Vet.*, 1986, 130, 205-214.
- Holmes JR*: Electrocardiography in the diagnosis of common cardiac arrhythmias in the horse. *Eq. Vet. Edu.*, 1990, 2, 24-27.
- Kiryu K, Kaneko K, Satoh H*: Cardiopathological observations on histogenesis of incomplete atrioventricular block in horses. *Jap. J. Vet. Sci.*, 1977, 39, 425-436.
- Kiryu K, Kaneko M, Kanemura T, Yoshihara T, Hasegawa M, Tomioka Y*: Cardiopathology of sinoatrial block in horses. *Jap. J. Vet. Sci.*, 1985, 47, 45-54.
- Matsui K, Amada A, Sawazaki H*: Second -degree atrioventricular block observed in a Thoroughbred foal at 2.5 months of age. *Jap. J. Vet. Sci.*, 1988, 47, 175-178.
- McGuirk SM, Muir WW*: Diagnosis and treatment of cardiac arrhythmias. *Vet. Clin. N. Am., Eq. Pract.*, 1985, 1, 353- 370
- Ohmura H, Hiraga A, Aida H, Huwakara M, Tsubone H*: Effect of initial handling and training on autonomic nervous function in young thoroughbreds. *Am. J. Vet. Res.*, 2002, 63, 1488-1491.
- Reef VB*: Frequency of cardiac arrhythmias and their significance in normal horses. *Proc. 7th., ACIVM Forum*, 1989, pp: 506-508.
- Smetzer DL*: Equine sinoatrial and second- degree atrioventricular heart block. Ph.D. thesis, The Ohio State University, U. S. A., 1967, p: 79.

(Received December 26, 2004; accepted April 25, 2005).

Reprints may be obtained from: Department of Clinical Studies, School of Veterinary Medicine, Shiraz University, P.O. Box 1731, Shiraz 71345, Iran. E-mail: rezakhania@yahoo.com