

Brief Communication

VESICAL HEMORRHAGES IN MALE ALEUTIAN MINK
CAUSED BY HYPERSENSITIVITY TO SULPHADIMIDINE

During an outbreak of *Salmonella* abortion in mink farms receiving food from a central feed plant, sulphamezathine (a 16 % solution of sulphadimidine sodium) was added to the food to combat the infection. After 3 days of medication, some males of the Aleutian type developed severe urinary bleedings. The serum concentration of the drug was not above the recommended value in 2 severely affected animals (1.5 and 1.7 mg/100 ml, respectively). Screening tests for the extrinsic (Thrombotest and Normotest) and intrinsic (cephalin time) coagulation mechanism, fibrinogen assay, fibrinolysis (plasma clot lysis time), and platelet count were not much different from normal. Coagulation or platelet defects did not therefore seem to be the cause of the bleedings. Some of the diseased animals died, and the only necropsy finding was a greatly distended urinary bladder filled with clotted blood. Histologically, hemorrhages and necrotic changes of varying severity were found in the vesical wall. In several cases, the arteries were the structures most evidently affected, indicating that the hemorrhages were due to vascular injury (Fig. 1). The damaged vessels were sporadically occluded by thrombi. The lesions were often most evident in subserosal arteries and in the relatively large arteries situated between the inner circular and the outer longitudinal muscular layer, whereas the submucosal structures were obscured by massive extravasations of red blood cells. Occasionally, the necrotic arteries were surrounded by incipient circumferential cellular accumulations, predominantly mononuclear cells, but some eosinophils were also present (Fig. 2). Thus, in these cases the vascular damage was similar to vascular lesions frequently accompanying viral plasmacytosis (periarteritis nodosa). The possibility exists that the animals were in an early developmental stage of plasmacytosis, but no extravascular changes suggesting plasmacytosis were discovered during the microscopic examination. Although other sulphonamides have occasionally shown toxic properties when administered to mink, this preparation has not, to the authors'

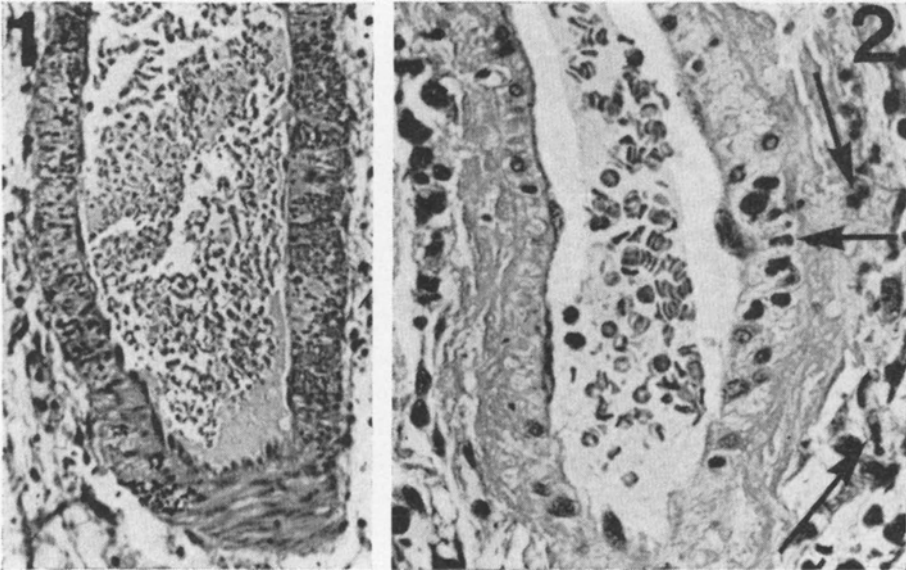


Figure 1. Necrotic vascular wall and massive transmural penetration of red blood cells. H & E, $\times 50$.

Figure 2. Necrotic arterial wall and incipient perivascular cellular accumulations. Slight cellular reaction is also visible within the damaged vessel wall. Some eosinophils are indicated by arrows. H & E, $\times 110$.

knowledge, previously been recorded as injurious to this species. The following experiment was performed to elucidate the toxicity of sulphadimidine sodium to male Aleutian mink.

Experimental observations

Eleven male Aleutian mink were given food to which sulphamezathine was added, initially in amounts calculated to correspond to a daily intake of approx. 0.1 g/kg body weight. As this dose was well tolerated, the supplement was increased. Three animals developed massive hematuria and died, after receiving various amounts of sulphamezathine, 0.3 g/kg b.w./day in 2 days, 0.5 g in 3 days and 0.3 g in 9 days, respectively. A picture similar to the field cases was found at necropsy. Three other mink also died, however without showing vesical bleedings. Histologically, varying degrees of hepatic and renal degeneration (acute nephrosis) were recognized; sulpha deposits were not observed in the kidneys in any case. Three animals did not reveal

any symptoms although they received 0.6 g/kg b.w. daily during the last 7 days of the experiment. Six Standard males were also included in the experiment and received high doses of sulphamezathine without developing hematuria.

Comments

The experiment reported above indicates a considerable individual variation in the tolerance to sulphadimidine sodium, even in Aleutian mink, which, perhaps with very rare exceptions, was the only genotype that reacted during the period of medication, when approx. 20,000 animals of different genotypes and of both sexes were exposed to the medicament. In these field cases, the possibility existed that the drug was somewhat unevenly distributed in the food. The observations obtained in the present experiment indicate that individual variations in tolerance play a major and possibly greater role than the dosage. Furthermore, there obviously exists a distinct sex difference as to the toxic effect, since only males were affected although several thousands of pregnant females also got the same feed and necessarily received considerably higher doses when the body weights were taken into account. The exceptional toxic effect of sulphamezathine may possibly be related to the abnormal lysosomal structure of Aleutian mink (*Chediak-Higashi* syndrome), but at this time, sufficient evidence is not available to explain the phenomena considered above. However, in humans, hypersensitivity to sulphonamides has been reported to provoke periarteritis nodosa (*Moeschlin* 1965).

K. Nordstoga

The National Veterinary Institute, Oslo, Norway,

A. Helgebostad

The Research Station for Fur Bearing Animals,
Veterinary College of Norway, Oslo, Norway,

G. Loftsgård

The Norwegian Fur Farmers Organization,
Research Division, Oslo, Norway,

H. Stormorken

The Institute for Thrombosis Research,
University Hospital, Oslo, Norway.

REFERENCE

- Moeschlin, S.*: Klinik und Therapie der Vergiftungen. 4. Auflage, Georg Thieme Verlag, Stuttgart 1965.