

From the Institute for Experimental Pathology, University of Iceland, Keldur, Reykjavik and the Department of Epidemiology, School of Hygiene and Public Health, Johns Hopkins University, Baltimore, Maryland, USA.

## EXPERIMENTAL VISNA IN ICELANDIC LAMBS \*

By

*Páll A. Pálsson, Gudmundur Georgsson,  
Gudmundur Pétursson and Neal Nathanson*

PÁLSSON, P. A., G. GEORGSSON, G. PÉTURSSON and N. NATHANSON: *Experimental visna in Icelandic lambs*. Acta vet. scand. 1977, 18, 122—128. — Icelandic lambs were inoculated intracerebrally with visna virus at 10 days of age and sacrificed 22—25 days after infection. Virus was isolated from all 5 inoculated animals, and pronounced periventricular lesions, typical of early visna, were seen in the 3 lambs with the most widespread infection. The response to the infection was very similar to that seen previously in adult Icelandic sheep.

In addition, 2 uninoculated lambs housed with the injected animals and sacrificed at the same time also became infected.

sheep; visna; slow infection; viral encephalomyelitis; C-type virus.

Visna, a progressive central nervous system disease of sheep, was initially recognized in Iceland 35 years ago. *Sigurdsson et al.* (1957) showed that visna was caused by a transmissible virus and included it as one of the prototype slow infections. Later work (*Sigurdsson et al.* 1960) demonstrated that visna could be produced by intracerebral injection of virus grown in tissue culture, and more recently the pathogenesis of the induced disease has been studied quite extensively in adult sheep (*Gudna-dóttir & Pálsson* 1965 a, *Pétursson et al.* 1976).

Current studies suggest that the lesions are immunologically induced (*Nathanson et al.* 1976) and that fetal American lambs can be infected but fail to develop lesions in the central nervous

---

\* This study was supported in part by a grant from the United States Public Health Service.

system (Narayan *et al.* in press). Also, it appears that the slowness of the infection is related to an *in vivo* restriction on visna replication (Haase *et al.* 1977).

These findings indicate that it would be useful to determine the response of newborn Icelandic lambs to infection to see whether age has any significant influence upon the extent of virus replication or upon the frequency, distribution or severity of lesions. Our current investigations (Pétursson *et al.*) document in detail the course of infection following intracerebral inoculation of a well-characterized strain of virus into adult Icelandic sheep, so that a semiquantitative comparison could be made with infection initiated in newborn lambs of the same breed under similar conditions.

In addition, the opportunity was taken to determine whether infection spreads readily by close contact between inoculated and uninoculated lambs.

#### MATERIALS AND METHODS

Lambs were obtained from a flock in which visna and maedi have never occurred. They were separated from their mothers at 2–5 days of age and fed milk substitute *ad libitum* from a “lamb bar”, a container fitted with several rubber nipples. The milk replacer consisted of skim-milk powder (83%), sheep tallow (15%), lecithin (1%), dicalcium phosphate (0.3%) and a vitamin-trace element mixture (0.2%). One kg of this was mixed with 4 l of lukewarm water. The lambs had free access to the container all the time, so problems with sudden overfeeding were avoided. On arrival at the laboratory each lamb was given an intramuscular injection of lamb dysentery serum (2 ml) and of a selenium-vitamin E mixture (Tokosel vet., Agrivet) (1 ml).

Of 10 lambs, 7 thrived and were in apparently good condition at sacrifice. Three animals failed to thrive (1 never learned to feed; another developed white muscle disease; the third developed intestinal volvulus), did not survive the experimental period, and are not included in the results.

Visna virus, strain 1514, was injected intracerebrally at 10 days of age in a dose of 0.3 ml (about  $10^6$  TCD<sub>50</sub>). The hair was cut, the skin disinfected, a local anesthetic injected and a hole drilled through the skull about 10 mm lateral to the midline and 15 mm anterior to the nuchal crista. A needle was inserted 20 mm in a ventromedial direction and the inoculum injected slowly

while withdrawing the needle. There was no apparent untoward effect of the injection. Methods for sacrifice, virus isolation and histological examination have been reported previously (*Pétursson et al.*).

### RESULTS

Observations were based on 7 lambs which remained in good condition throughout the 22—25 days period following infection. Of these, 5 were inoculated and 2 (housed with the inoculated animals) served as uninoculated contacts. The data are summarized in Table 1.

Table 1. Virus isolations and histological grade in inoculated Icelandic lambs and their uninoculated contacts, 25 days after infection with visna virus.

|                    | Inoculated* |      |      |       |       |       | Contact       |      |      |
|--------------------|-------------|------|------|-------|-------|-------|---------------|------|------|
|                    | 1603        | 1604 | 1605 | 1606  | 1607  | total | percentage    | 1610 | 1611 |
| Histological grade | 0           | 3    | 0    | 4     | 4     |       |               | 0    | 0    |
| CSF                |             |      |      | ND    | ND    | 0/3   | 65<br>(15/23) | ND   | ND   |
| Plexus             |             | +    | +    | +     | +     | 4/5   |               |      | +    |
| Medulla            |             | +    | +    | +     | +     | 4/5   |               |      |      |
| Cerebellum         |             | +    |      | +     | +     | 3/5   |               |      |      |
| Cord               |             | +    | +    | +     | +     | 4/5   |               |      |      |
| Buffy coat         |             | +    |      | +     | +     | 3/5   | 54<br>(13/24) |      |      |
| Spleen             | +           | +    |      | +     | +     | 4/5   |               |      | +    |
| Mediastinal ln.    |             | +    |      | +     | +     | 3/5   |               |      | +    |
| Mesent. ln.        |             |      |      | +     | +     | 2/5   |               |      | +    |
| Marrow             |             |      |      | ND    | +     | 1/4   |               |      |      |
| Tonsil             |             |      |      | +     |       | 1/5   |               |      |      |
| Thymus             |             |      |      | +     | +     | 2/5   |               |      |      |
| Lung               |             | +    | +    | +     | +     | 4/5   |               | +    |      |
| Overall            | 1/13        | 8/13 | 4/13 | 11/11 | 11/12 |       |               | 4/12 | 1/12 |

\*Inoculated lambs were infected by intracerebral injection of  $10^6$  TCD<sub>50</sub> of strain 1514. Contacts were housed in the same cubicle.

Virus was isolated from all 5 inoculated lambs, most frequently from the central nervous system and lymphoid tissues. Tissues were tested by 3 methods (Table 2). Homogenates yielded virus more often than did explants. In many instances 1 or 2 blind passages were required before detection of a cytopathic effect.

Table 2. Virus isolations from 5 Icelandic lambs inoculated intracerebrally with visna virus: Comparison of isolation techniques\*.

| Method                    | Isolations |              |      | Frequency |    |
|---------------------------|------------|--------------|------|-----------|----|
|                           | 0-passage  | 1—2 passages | neg. | +/T       | %  |
| Explant                   | 8          | 17           | 44   | 25/69     | 36 |
| Explant and cocultivation | 7          | 22           | 40   | 29/69     | 42 |
| Homogenate                | 17         | 6            | 21   | 23/44     | 52 |

\* Tissues include: plexus choroideus, medulla, cerebellum, spinal cord, spleen, lymph nodes, lung and bone marrow.

Relatively severe histological lesions, grade 3 and 4 on a scale of 1—6 (Pétursson *et al.* 1976), were seen in the 3 inoculated lambs with the most widespread infection (Table 1). They consisted mainly of more or less confluent subependymal inflammation (Fig. 1) bordering a considerable part of the ventricular system. Occasionally inflammatory infiltrates, mainly perivascular cuffs, extended into adjacent grey or white matter (Figs. 1 and 2). The infiltrates were composed of mononuclear cells (Fig. 2), mainly lymphocytes, monocytes and/or macrophages and some plasma cells, and were often accompanied by some astrocytic and microglial reaction. Neurons were spared and myelin breakdown was minimal. In the choroid plexus the infiltrates varied from slight to heavy with prominent lymphoid nodules (Fig. 3). In the leptomeninges of the brain and of the spinal cord a slight infiltration of mononuclear cells was found. The peripheral nervous system was intact and no constant lesions, which could definitely be associated with visna, were seen in the lungs or other organs.

The 2 uninoculated contacts yielded virus but showed no lesion of the nervous system (Table 1).

## DISCUSSION

Although the number of animals was small the results of this study clearly answered several questions:

Newborn lambs inoculated intracerebrally with visna virus experienced an infection much like that seen in older sheep. The distribution of virus was similar, concentrating in the central nervous system and lymphoid tissues, and the overall frequency

of isolation by tissue was also parallel to that previously observed. Furthermore the comparison of 3 isolation techniques and the requirement for blind passage were very like our prior results. Many tissues yielded minimal levels of free infective virus, but in a considerable number explanation was required for isolation. Thus it appears that the virus-cell interaction was similar in newborns and adults. This is consistent with the conclusions reached by other workers (*Narayan et al.*, in press) that the restriction on replication, which apparently plays an important role in the slowness of the infection, is not age-determined.

These results are also consistent with an earlier study (*Gudnadóttir & Pálsson 1965 a*), which showed that newborn Icelandic lambs could be infected by the pulmonary route.

The frequency, severity and character of the lesions were parallel to those observed at 3—4 weeks after infection in older sheep (*Pétursson et al. 1976*). Since the sheep is immunologically responsive at birth, it is reasonable that immunologically mediated lesions would appear.

Recent studies revealed no or minimal lesions in fetal and neonatal American lambs (*Narayan et al. 1973*, in press). This indicates a difference in response in different sheep breeds, and can not be explained on the basis of age alone.

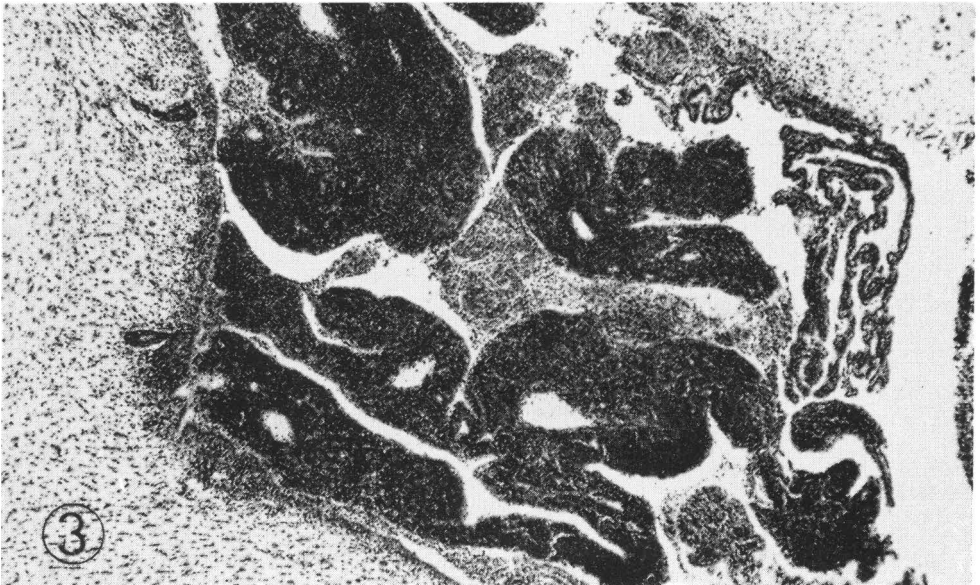
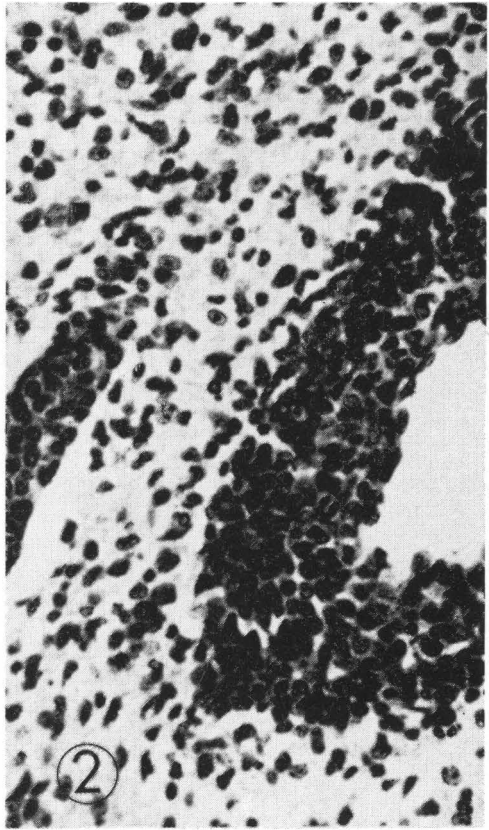
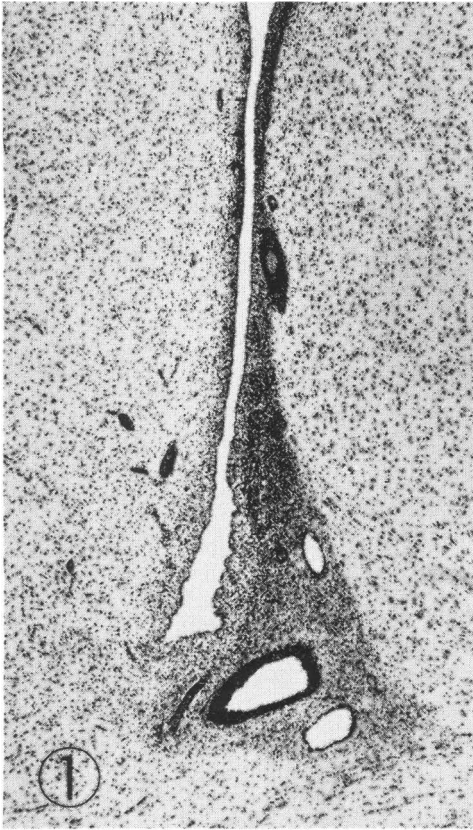
It is well established that young sheep from clinically affected mothers usually are infected and are at high risk of clinical maedi or visna at an early age. It is not entirely clear whether visna virus can be transmitted as a congenital infection (*Hoff-Jørgensen* in press), a possibility which must be seriously considered for all C-type viruses. However, some studies have suggested (*de Boer 1970*, *Gudnadóttir 1974*) that postnatal transmission is important. Both colostrum and pharyngeal secretions of affected ewes can carry the virus and could play a role in early infection of lambs.

---

Figure 1. Lateral ventricle. Confluent subependymal inflammation. Perivascular infiltrates in adjacent grey matter. Galloxyanin-Eosin,  $\times 40$ .

Figure 2. Detail of Fig. 1. Perivascular infiltrates composed of mononuclear cells, mainly lymphocytes, accompanied by astrocytic and microglial reaction. Galloxyanin-Eosin,  $\times 385$ .

Figure 3. Choroid plexus of lateral ventricle. Heavy inflammation with lymphoid nodules. Galloxyanin-Eosin,  $\times 40$ .





The present data indicating lamb-to-lamb transmission within a 3 week period add further documentation to the potential importance of lateral spread of infection during the early neonatal period.

#### ACKNOWLEDGEMENTS

For valuable technical assistance the authors are indebted to R. E. Lutley, B.Sc., Örbrún Guðmundsdóttir, Adalheidur Gunnlaugsdóttir, Ragnhildur Jóhannesdóttir and Elsa Benediksdóttir.

#### REFERENCES

- De Boer, G. F.*: Zwøegerziekte, a persistent infection in sheep. Thesis, Utrecht 1970.
- Guðnadóttir, M.*: Visna-maedi in sheep. *Progr. med. Virol.* 1974, *18*, 336—349.
- Guðnadóttir, M. & P. A. Pálsson*: Successful transmission of visna by intrapulmonary inoculation. *J. infect. Dis.* 1965 a, *115*, 217—225.
- Guðnadóttir, M. & P. A. Pálsson*: Host-virus interaction in visna infected sheep. *J. Immunol.* 1965 b, *95*, 1116—1120.
- Haase, A. T., L. Stowring, O. Narayan, D. Griffin & D. Price*: Slow persistent infection caused by visna virus: role of host restriction. *Science* 1977, *195*, 175—177.
- Hoff-Jørgensen, R.*: Slow virus infection. Maedi-visna and bovine enzootic leukemia as examples. *Growing Points in Veterinary Science*, in press.
- Narayan, O., A. M. Silverstein, D. Price & R. T. Johnson*: Visna virus infection of American lambs. *Science* 1973, *183*, 1202—1203.
- Narayan, O., D. E. Griffin & A. M. Silverstein*: Slow virus infection: replication and mechanisms of persistence of visna virus in sheep. *J. infect. Dis.*, in press.
- Nathanson, N., H. Panitch, P. A. Pálsson, G. Pétursson & G. Georgsson*: Pathogenesis of visna. II. Effects of immunosuppression upon early CNS lesions. *Lab. Invest.* 1976, *35*, 444—451.
- Pétursson, G., N. Nathanson, G. Georgsson, H. Panitch & P. A. Pálsson*: Pathogenesis of visna. I. Sequential virologic, serologic and pathologic study. *Lab. Invest.* 1976, *35*, 402—412.
- Sigurdsson, B., P. A. Pálsson & H. Grimsson*: Visna, a demyelinating transmissible disease of sheep. *J. Neuropath. exp. Neurol.* 1957, *16*, 389—403.
- Sigurdsson, B., H. Thormar & P. A. Pálsson*: Cultivation of visna virus in tissue culture. *Arch. ges. Virusforsch.* 1960, *10*, 368—381.

#### SAMMENDRAG

##### *Ekspærimental visna hos islandske spædlam.*

Islandske spædlam blev injiceret intracerebralt med 0,3 ml af visnavirus ( $10^6$  TCD<sub>50</sub>), når de var 10 dage gamle. Efter 22—25 dage blev lammene aflivet. Visnavirus blev isoleret fra alle 5 lam, og der



blev observeret udtalte periventrikulære infiltrationer i centralnervesystemet, mest hos de 3 lam, hvor man ved dyrkning fandt den største udbredelse af virus i forskellige organer. Disse patologiske forandringer var typiske visnaforandringer på tidligt stadium.

Reaktionen hos unge lam overfor infektion med visna virus ligner meget den, man observerer hos voksne får.

To lam, som ikke blev injiceret med virus, men anbragt i sti sammen med de inficerede lam og fik mælk fra det samme drikkekar, blev smittet med visnavirus i løbet af de godt 3 uger kontakten varede.

*(Received December 23, 1976).*

Reprints may be requested from: P. A. Pálsson, Institute for Experimental Pathology, University of Iceland, Keldur, Reykjavik, Iceland.