

From the Department of Microbiology and Immunology and the Department of Pathology, Norwegian College of Veterinary Medicine, Oslo, and the State Veterinary Laboratory for Northern Norway, Harstad, Norway.

# **Corynebacterium Pseudotuberculosis Infection in Goats VII.**

## **Clinical, Pathological, Serological and Hematological Changes after Subcutaneous Inoculation of the Organism**

By *Gudmund Holstad* and *Jon Teige jr.*

**Holstad, G. and J. Teige jr.: Corynebacterium pseudotuberculosis infection in goats VII. Clinical, pathological, serological and hematological changes after subcutaneous inoculation of the organism. Acta vet. scand. 1988, 29, 287-294.** – Six castrated male kids from 2 herds free from caseous lymphadenitis, were inoculated subcutaneously with about 1 million colony forming units of a *Corynebacterium pseudotuberculosis* strain isolated from goat. The animals exhibited a febrile response and marked inflammatory reaction at the inoculation site during the first days after infection. Post mortem examination carried out 2 months after inoculation revealed abscesses in the regional lymph node (Inn. subiliaci) of all animals, in 3 of which lesions also appeared in other lymph nodes. The antibody titre (mean value) in the bacterial agglutination test peaked during the first 2 weeks following inoculation, while the titre in the hemolysis inhibition test began to rise from 2-3 weeks after the infection and continued to increase during the rest of the investigation period (9 weeks after inoculation). Hemoglobin and hematocrit levels decreased significantly after inoculation, and remained below the preinfection levels for 2 weeks. A significant leucocytosis was also seen during the same period. The present investigation indicates that subcutaneous inoculation with *C. pseudotuberculosis* might be a suitable challenge system to study the efficacy of vaccines against caseous lymphadenitis in goats.

experimental infection; inflammation; abscesses; antibodies; hemoglobin; hematocrit; leucocytes.

### **Introduction**

*Corynebacterium pseudotuberculosis* causes caseous lymphadenitis in sheep and goats. Lesions similar to those seen in field cases develop following experimental infection. Numerous routes of infection, inter alia intradermal, intratracheal, subcutaneous and intravaginal have been tried experimentally in sheep (*Nagy* 1976). Inoculation by such routes resulted in abscess formation in local

lymph nodes. Intradermal, subcutaneous and subgingival inoculation of *C. pseudotuberculosis* has also been observed to result in abscess formation in regional lymph nodes in goats (*Abdel-Hamid* 1973, *Ashfaq & Campbell* 1980, *Brown et al.* 1985). Intravenous injection of large doses of *C. pseudotuberculosis* often results in toxemia and death in non-immunized sheep while animals that survive the infection develop ab-

ssesses in internal organs (Cameron *et al.* 1972). Similar results have been obtained after intravenous inoculation of the organism in goats (Holstad & Teige 1988). Abdel-Hamid (1973) concluded that the clinical manifestation in goats to experimental infection with *C. pseudotuberculosis* varies depending upon dose and route of infection. Different doses of the organism have been tried for experimental infection, and Ashfaq & Campbell (1980) found 1 million colony forming units to be a suitable infective dose for subcutaneous or intradermal inoculation in goats.

The humoral immune response to experimental infection with *C. pseudotuberculosis* in goats has been measured by different tests. Abdel-Hamid & Zaki (1973) found that antibodies to *C. pseudotuberculosis* in the goat could be detected 4–8 weeks after subcutaneous or intradermal infection using the mouse protection test and the antihemolysin inhibition test. Brown *et al.* (1985) demonstrated antibodies in goat sera by the synergistic hemolysis-inhibition test within 1 month after intradermal inoculation of the organism. Hematological values in goats after intradermal and intranasal inoculation of *C. pseudotuberculosis* have been measured by Brown *et al.* (1985). A slight persistent leucocytosis was observed in all animals.

The main purpose of the present investigation was to study clinical and pathological changes after subcutaneous inoculation of *C. pseudotuberculosis* in goats, and to evaluate subcutaneous inoculation as a challenge system for measuring the efficacy of vaccines against caseous lymphadenitis. The purpose was further to make a study on the humoral immune response and hematological changes following subcutaneous inoculation of the organism.

## Materials and methods

### Animals

The material comprised 6 castrated male kids, originating from 2 herds, both of which participated in the same goat "breeding circle"\*. In one of these herds, clinical and serological examinations of animals had failed to reveal any evidence of caseous lymphadenitis. In the other herd, no examinations concerning the occurrence of caseous lymphadenitis had been carried out. Information from the farmer indicated, however, that the herd was free from the infection.

The kids were placed in thoroughly cleaned and disinfected pens at 3 weeks of age. They were fed an acidified milk substitute, hay and pelleted calf concentrates, as well as supplementary minerals and water.

### Inoculation

A *C. pseudotuberculosis* strain (NVH 2586\*\*) isolated from goat was used for inoculation. A previous investigation (Holstad & Teige 1988) revealed that a dose of about 1 million colony forming units of this strain injected intravenously, caused death in kids lacking antibodies against the organism. The same inoculum was used in the present investigation. The bacterial suspension was prepared according to Holstad & Teige (1988). Each animal was inoculated with the suspension at the age of 4 1/2 months. The suspension was given subcutaneously, 1 cm below the right *Inn. subiliaci*.

---

\* Breeding system practised in Norway in which several herds share the use of the same breeding males.

\*\* Culture collection at the Department of Microbiology and Immunology, Norwegian College of Veterinary Medicine, Oslo.

#### *Serological examination*

Blood samples were collected from all the kids before they were inoculated, and at one week intervals afterwards. Sera were prepared according to standard procedures and stored at  $-20^{\circ}\text{C}$ . All the sera were examined for antibodies to *C. pseudotuberculosis* using the bacterial agglutination test (BAT) and the hemolysis inhibition test (HIT) (Holstad 1986a). Titre values were expressed as  $\log_{10}$  to the reciprocal value of the highest positive serum dilution in both tests, and positive titre (T) was stipulated as  $T \geq 2.1$  in BAT and  $T \geq 0.6$  in HIT (Holstad 1986a).

#### *Hematological examinations*

Blood samples for hematological examinations were collected from all the kids when they were inoculated and 2 days post-inoculation. Further samples were collected 1, 2, 3, 6 and 9 weeks after inoculation. Hematocrit and hemoglobin values were determined and total leucocytes were counted according to standard procedures. Differential counts of neutrophils and lymphocytes were carried out.

#### *Clinical examinations*

The kids were inspected and palpated for lesions, and body temperature measured each day during the 2 weeks following inoculation. This procedure was thereafter repeated once weekly. Swellings at the inoculation site and in the regional lymph node, pus formation and pain were recorded.

#### *Post mortem examinations*

Two months after inoculation the animals were killed, weighed, and necropsy performed.

Sections for histological examination were collected from the lnn. subiliaci regional to the inoculation site. Some sections of the opposite lnn. subiliaci were also collected in

order to obtain a basis for lymph node evaluation. All the sections were stained with hematoxylin and eosin.

Samples for bacteriological examination were taken from abscesses. Cultivation was carried out on blood agar plates, the plates being incubated for 48 h at  $37^{\circ}\text{C}$  in 10%  $\text{CO}_2$  atmosphere. Bacterial colonies suspected to be *C. pseudotuberculosis* were identified according to Buchanan & Gibbons (1974).

#### *Statistical analysis*

Statistical calculations were carried out using Wilcoxon Signed Ranks Test.  $P \leq 0.05$  was taken to indicate statistical significance.

### **Results**

#### *Serological examinations*

Fig. 1 shows the sequential titre values in BAT and HIT.

The titres in BAT increased significantly during the first 2 weeks following inoculation and decreased subsequently for a period of 2–3 weeks. All kids had positive titres from the second week onwards.

HIT-titres started to increase 2–3 weeks following inoculation and increased further during the rest of the investigation period. The increase did not, however, become significant until 7 weeks after inoculation, at this time 5 kids being positive in the test. All kids were positive in HIT 9 weeks after inoculation.

#### *Hematological examinations*

The hematocrit and hemoglobin values decreased significantly after inoculation, and remained below the preinfection levels for 2 weeks (Fig. 2).

The number of leucocytes increased significantly during the first week post-inoculation (Fig. 3). Differential counts revealed a sig-

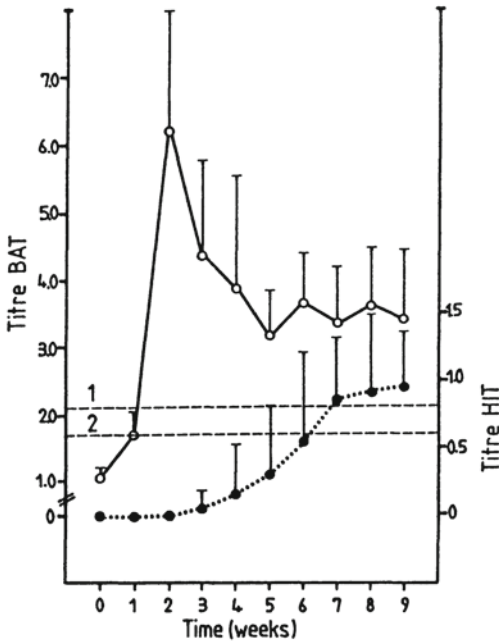


Figure 1. Mean titres + standard deviation for antibodies against *C. pseudotuberculosis* for 6 kids in the bacterial agglutination test (BAT) (○—○), and in the hemolysis inhibition test (HIT) (●.....●).

About 1 million colony forming units of *C. pseudotuberculosis* were given on day 0. Horizontal, dotted lines 1 and 2 indicate border between positive and negative titres in BAT and HIT, respectively.

nificant increase in neutrophils and decrease in lymphocytes during the same period (Fig. 3).

#### Clinical examination

Within a day after inoculation, the animals' mean body temperature increased from 39.5 to 40.8°C. The temperature dropped to normal values during the following week.

In each kid swelling developed at the inoculation site and in the regional lymph node within a day after inoculation. Pus formation was shown at the inoculation site few

days afterwards. The kids showed signs of discomfort on palpation of the lesions. All but one animal had edema over the abdomen during the first 5 days after inoculation. Two months later, swellings at the inoculation site could not be detected in 5 kids. The size of the regional lymph node increased during the investigation period in all animals, and in one kid pus was discharged from the lymph node 8 weeks after inoculation.

#### Post mortem examination

At sacrifice body weights varied between 23,5–29,0 kg. All the kids developed abscesses in the regional lymph node, lesions being also demonstrated in other lymph nodes in 3 kids (Table 1). Histological examination of the regional lymph nodes revealed a broad cortex with an increase in the number of secondary follicles, and a moderate proliferation of cells in the paracortex area. Plasma cell infiltrations could be seen in the medullary cords.

*C. pseudotuberculosis* in pure culture was isolated from all the abscesses examined bacteriologically (Table 1).

#### Discussion

Lesions of caseous lymphadenitis developed in all kids after inoculation. The animals showed a febrile response and marked inflammatory reactions during the first days after inoculation. The acute symptoms gradually subsided in severity as the disease progressed towards a chronic suppurative state. *Abdel-Hamid* (1973) inoculated goats subcutaneously with different doses of a broth culture of *C. pseudotuberculosis*, and found that animals given large doses died, while those given small doses showed moderate fever, local abscesses and enlargement of regional lymph nodes. *Ashfaq & Campbell* (1980) demonstrated abscesses in regio-

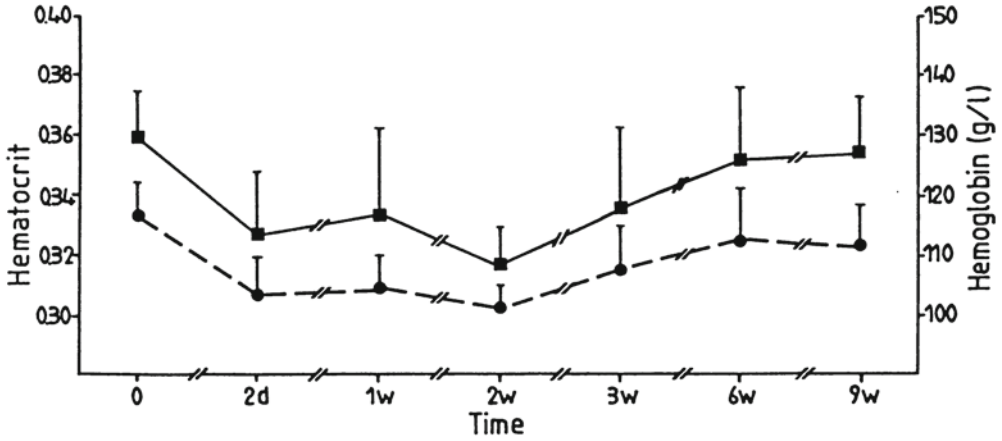


Figure 2. Mean hematocrit (■—■) and hemoglobin (●—●) values + standard deviation for 6 kids at different times after inoculation with *C. pseudotuberculosis*. About 1 million colony forming units of *C. pseudotuberculosis* were given on day 0. d) Days after inoculation, w) Weeks after inoculation.

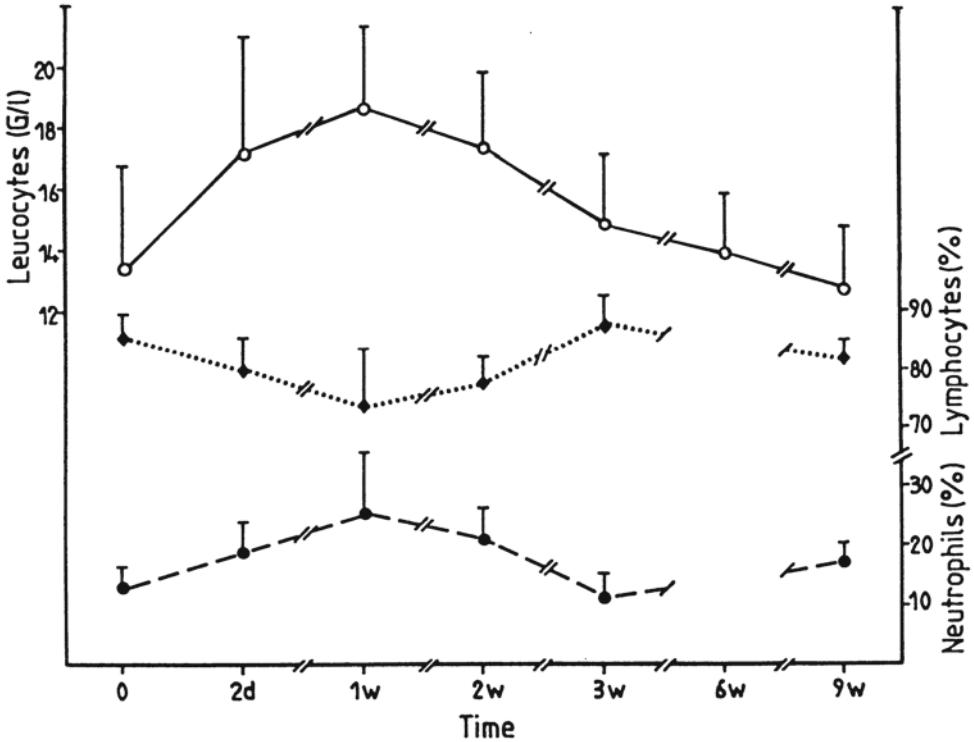


Figure 3. Mean leucocyte number (○—○) and percentage of neutrophils (●—●) and lymphocytes (◆····◆) + standard deviation for 6 kids at different times after inoculation with *C. pseudotuberculosis*. About 1 million colony forming units of *C. pseudotuberculosis* were given on day 0. d) Days after inoculation, w) Weeks after inoculation.

Table 1. Results from the post mortem examination of 6 kids showing a) presence (+) or absence (-) of abscesses and b) isolation (+) of *Corynebacterium pseudotuberculosis* from the abscesses.

Localization	Animal number											
	1		2		3		4		5		6	
	a	b	a	b	a	b	a	b	a	b	a	b
Inoculation site	+	+	+	+	+	+	+	+	+	+	-	-
Lnn. subiliaci*	+	+	+	+	+	+	+	+	+	+	+	+
Lnn. ileofemorales	+	+	+	+	-	-	-	-	-	-	+	ne
Lnn. broncheales	+	ne	-	-	-	-	-	-	-	-	-	-
Lnn. mediastinales	+	ne	+	+	-	-	-	-	-	-	-	-
Lnn. retropharyngeales	+	+	-	-	-	-	-	-	-	-	-	-

\*) Regional lymph node.

ne) Not examined.

nal lymph nodes in goats inoculated subcutaneously, intradermally or submucosally with 1 million colony forming units of the organism. Spread of infection from the inoculation site was detected in all animals in the present study. Suppurative lesions in lnn. ileofemorales in 3 kids indicated that the organism had passed intervening lymph nodes from the inoculation site. *Brown et al.* (1985) demonstrated a prominent inflammatory reaction in blood and lymphatic vessels at the site of injection 2 days after intradermal inoculation. They demonstrated that the endothelium displayed various degrees of reaction, degeneration and necrosis. *Jolly* (1965) observed that the exotoxin of *C. pseudotuberculosis* acted on the local vascular bed. *Carne & Onon* (1978) showed that the exotoxin had lytic effect on endothelial cells in vitro, and they concluded that the exotoxin was important as a permeability factor, resulting in local spread and enhanced chance of dissemination of the organism.

The present investigation indicates that antibodies against *C. pseudotuberculosis* can be detected earlier by BAT than by HIT after experimental infection. Investigations car-

ried out in newly infected herds also indicate that infected animals can be identified earlier by BAT than by HIT following natural infection with the organism (*Holstad* 1986b). In the present investigation, high levels of antibodies were detected in BAT at 2 weeks following infection in most of the kids, while in HIT, antibodies were detected for the first time, and then only in one animal, about one month after inoculation. It was not before 2 months post-inoculation that all animals became positive in HIT. The results obtained in HIT in the present study are in accordance with the results obtained by *Abdel-Hamid & Zaki* (1973). Similar to HIT, the tests used by the cited author measure antibodies against the exotoxin of *C. pseudotuberculosis*.

The hematological examinations revealed that the hematocrit and hemoglobin decreased after inoculation, and remained low for the following 2 weeks. *Nairn et al.* (1977) placed material from active lesions of caseous lymphadenitis on fresh skin cuts in seronegative sheep and found that the packed cell volume fell from 31,65 % at inoculation to 21,1 % 7 days later. *Cameron et al.* (1972) demonstrated a dramatic drop in hematocrit

and hemoglobin values in sheep given a fresh vaccine of *C. pseudotuberculosis* subcutaneously, and concluded that the toxic effect of the vaccine was due to the exotoxin. The exotoxin of *C. pseudotuberculosis* has been shown to have a toxic effect on erythrocytes from sheep and rabbits (Carne & Onon 1978). The changes in hematocrit and hemoglobin observed in the kids in the present investigation might well have been a result of such an effect on the erythrocytes. A leucocytosis was recorded for 2 weeks after inoculation in the animals in the present study, a finding which is in accordance with observations made by Brown *et al.* (1985).

All the kids in the present investigation came from herds free from caseous lymphadenitis, and serological examinations indicated that they were not infected with *C. pseudotuberculosis* before inoculation. The kids survived the inoculation, but showed, for a short period of time, acute clinical symptoms. Goat farmers have reported that signs of general ill health can be seen in several animals during the period immediately following the first observation of caseous lymphadenitis in a herd. The clinical symptoms registered in the animals in the present study probably resemble those observed after natural infection in unprotected goats. All the kids in the present investigation developed abscesses after inoculation. A challenge system consisting of about 1 million colony forming units of *C. pseudotuberculosis* inoculated subcutaneously, seems therefore, to be suitable for assessing the efficacy of vaccines against caseous lymphadenitis.

#### Acknowledgements

We thank the Department of Medicine 1, Norwegian College of Veterinary Medicine, for assistance in performing the hematological examina-

tions. The investigation was supported by grants from the Agricultural Research Council of Norway.

#### References

- Abdel-Hamid YN: A clinical investigation on the manifestation of goats to experimental infection with *C. ovis*. *J. Egypt. vet. med. Ass.* 1973, 33, 45-53.
- Abdel-Hamid YN, Zaki MM: Immune response of goats artificially infected with *C. ovis*. *J. Egypt. vet. med. Ass.* 1973, 33, 137-140.
- Ashfaq MK, Campbell SG: Experimentally induced caseous lymphadenitis in goats. *Amer. J. vet. Res.* 1980, 41, 1789-1792.
- Brown CC, Olander HJ, Biberstein EH: Serologic response and lesions in goats experimentally infected with *Corynebacterium pseudotuberculosis* of caprine and equine origins. *Amer. J. vet. Res.* 1985, 46, 2322-2326.
- Buchanan RR, Gibbons NE: In *Bergey's Manual of Determinative Bacteriology*, 8th ed. Williams & Wilkins, Baltimore 1974, p. 604.
- Cameron CM, Minnaar JL, Engelbrecht MM, Purdom MR: Immune response of merino sheep to inactivated *Corynebacterium pseudotuberculosis* vaccine. *Onderstepoort J. vet. Res.* 1972, 39, 11-24.
- Carne HR, Onon EO: Action of *Corynebacterium ovis* exotoxin on endothelial cells of blood vessels. *Nature (London)* 1978, 271, 246-248.
- Holstad G: *Corynebacterium pseudotuberculosis* infection in goats I. Evaluation of two serological diagnostic tests. *Acta vet. scand.* 1986a, 27, 575-583.
- Holstad G: *Corynebacterium pseudotuberculosis* infection in goats IV. Course of the infection in two recently infected goat herds. *Acta vet. scand.* 1986b, 27, 609-616.
- Holstad G, Teige jr. J: *Corynebacterium pseudotuberculosis* infection in goats VI. Clinical and pathological changes after intravenous inoculation of the organism. *Acta vet. scand.* 1988, 29, 281-286.
- Jolly RD: The pathogenic action of the exotoxin of *Corynebacterium ovis*. *J. comp. Path.* 1965, 75, 417-431.

Nagy G: Caseous lymphadenitis in sheep – methods of infection. J. S. Afr. vet. med. Ass. 1976, 47, 197–199.

Nairn ME, Robertson JP, McQuade NC: The control of caseous lymphadenitis in sheep by vaccination. Proc. 54th Ann. Conf. Aust. vet. Ass., Perth 1977, pp. 159–161.

#### Sammendrag

*Corynebacterium pseudotuberculosis* infeksjon hos geit VII. Kliniske, patologiske, serologiske og hematologiske forandringer etter subcutan inokulering av bakterier.

Seks kastrede bukkkje fra 2 besetninger fri for kaseøs lymfadenitt ble inokulert subcutant med ca. 1 million kolonidannende enheter av en *Corynebacterium pseudotuberculosis* stamme isolert fra geit. Dyrene fikk feber og en uttalt betennelse

på inokuleringsstedet de første dagene etter inokulering. Obduksjon ble foretatt 2 måneder etter belastning, og alle dyrene hadde da abscesser i den regionale lymfeknuten (Inn. subiliaci). Hos 3 kje ble det også påvist lesjoner i andre lymfeknuter. Antistofftiteret (gjennomsnittsverdien) målt ved bakterieagglutinasjonstest økte til høyeste verdi i løpet av de 2 første ukene etter inokulering, mens det ved antihemolysintest økte fra 2 uker etter infeksjon og resten av undersøkelsesperioden (9 uker etter inokulering). Hematokritt- og hemoglobinverdiene avtok etter inokulering og var lavere enn før inokulering i de 2 følgende ukene. I samme periode ble det påvist leucocytose hos dyrene. Det konkluderes med at det er hensiktsmessig å benytte subcutan belastning med *C. pseudotuberculosis* til å studere effektiviteten til vaksiner mot kaseøs lymfadenitt hos geit.

(Received January 4, 1988).

Reprints may be requested from: Gudmund Holstad, Department of Microbiology and Immunology, Norwegian College of Veterinary Medicine, P.O. Box 8146, Dep., N-0033 Oslo 1, Norway.