

Description of the Infection Status in a Norwegian Cattle Herd Naturally Infected by *Mycobacterium avium* subsp. *paratuberculosis*

By G. Holstad¹, Ó. G. Sigurðardóttir¹, A. K. Storset², J. Tharaldsen¹, O. Nyberg¹, J. Schönheit² and B. Dønne¹

¹National Veterinary Institute, P.O. Box 8156 Dep., N-0033 Oslo, Norway, ²National Veterinary Institute, Bon-telabo 8, 5003 Bergen, Norway, ³Norwegian School of Veterinary Science, P.O. Box 8146 Dep., N-0033 Oslo, Norway.

Gudmund H, Sigurðardóttir OG, Storset AK, Tharaldsen J, Nyberg O, Schönheit J, Dønne B: Description of the infection status in a Norwegian cattle herd naturally infected by *Mycobacterium avium* subsp. *paratuberculosis*. Acta vet. scand. 2005, 46, 45-56. – The Norwegian surveillance and control programme for paratuberculosis revealed 8 seroreactors in a single dairy cattle herd that had no clinical signs of *Mycobacterium avium* subsp. *paratuberculosis* (*M. a. paratuberculosis*) infection. Paratuberculosis had been a clinical problem in goats several years previously in this herd. All 45 cattle were culled and a thorough investigation of the infection status was conducted by the use of interferon- γ (IFN- γ) immunoassay, measurement of antibodies, and pathological and bacteriological examination.

In the IFN- γ immunoassay, 9 animals gave positive results, and 13 were weakly positive, while 19 animals were negative. In the serological test, 10 animals showed positive reactions, and 5 were doubtful, while 30 animals gave negative reactions. There appeared to be a weak trend toward younger animals having raised IFN- γ and older animals having raised serological tests. Histopathological lesions compatible with paratuberculosis were diagnosed in 4 animals aged between 4 and 9 years. Three of these animals had positive serological reaction and one animal gave also positive results in the IFN- γ immunoassay. Infection was confirmed by isolation of *M. a. paratuberculosis* from 2 of these 4 animals. One single bacterial isolate examined by restriction fragment length polymorphism (RFLP) had the same profile, B-C1, as a strain that had been isolated from a goat at the same farm several years previously.

Despite many animals being positive in one or both of the immunological tests, indicative of a heavily infected herd, none of the animals showed clinical signs and only one cow was shown to be shedding bacteria. A cross-reaction with other mycobacteria might have caused some of the immunoreactions in these animals. It is also possible that the Norwegian red cattle breed is resistant to clinical infection with *M. a. paratuberculosis*.

Mycobacterium paratuberculosis; paratuberculosis; cattle; diagnosis; IFN- γ

Introduction

Paratuberculosis is a chronic infectious enteritis in ruminants caused by *M. a. paratuberculosis*. The disease is widely distributed, and the prevalence of infection varies in different parts of the world (Olsen et al. 2002).

In Norway, paratuberculosis has been endemic in the goat population, while only sporadic cases have been diagnosed in cattle and sheep. From 1966 to 1999, *M. a. paratuberculosis* was isolated from 898 goats in 186 herds, from 20

cattle in 12 herds and from three sheep in one herd (Djønne et al. 2001b). The majority of the affected herds were located in Western Norway. In 1996, a national surveillance and control programme for bovine paratuberculosis was implemented in Norway. During the first two years of the programme, samples from imported cattle, and cattle that had been in contact with the former, were examined by serology, histopathology and/or bacteriological culture from faecal samples or organs. In total, 1403 animals from 134 herds were examined by serology, whereof approximately 11% were positive. The infection, however, could only be verified in seven animals from four herds. In 1998 and 1999, the programme was expanded to include Norwegian cattle with no connection to imported animals. Initially, serological examinations were used to screen the herds, and on average about 8% of the animals tested were found to be seroreactors (Djønne et al. 2001a). These findings might indicate that the infection is more widespread in the Norwegian cattle population than has been assumed during the last 20 years. However, seroreactors could be the result of cross-reactions between *M. a. paratuberculosis* and other microbes. Such cross-reactions are well known between mycobacteria (Chiodini et al. 1984, Jungersen et al. 2002, Reichel et al. 1999).

M. a. paratuberculosis infection in a herd is a dynamic process, where the infection status is dependant on many factors including the number of animals shedding bacteria and the management conditions (Johnson-Ifearulundu & Kaneene 1998, Obasanjo et al. 1997, Whittington & Sergeant 2001). Isolation of *M. a. paratuberculosis* by cultivation is the definitive method for the detection of an infection in a herd. It is, however, well known that animals might be infected without shedding bacteria. Serological, pathological and bacteriological methods have singly or together been used to

describe the infection status in naturally infected cattle (Eamens et al. 2000, Gasteiner et al. 2000, Jakobsen et al. 2000, Jubb & Galvin 2000, Nielsen et al. 2002, Reichel et al. 1999, Whitlock & Buergelt 1996), and an IFN- γ test has been evaluated for diagnosis of the infection in young cattle (Jungersen et al. 2002, McDonald et al. 1999). However, there are few studies that include immunological, pathological and bacteriological analyses of the total cattle population in a herd.

In one cattle herd included in the Norwegian surveillance and control programme for paratuberculosis, 8 of 18 dairy cows were found to have positive seroreactions. Four of these animals had high levels of antibodies. Two of the animals with high antibody levels were slaughtered, and histopathological and bacteriological examination revealed paratuberculosis in 1 animal. The farmer decided to cull the herd, and all the animals were sent to slaughter 9 months after paratuberculosis was diagnosed in the herd. The aim of the present study was to investigate thoroughly the infection status in this herd at the time of slaughter, by the use of IFN- γ immunoassay, and serological, pathological, and bacteriological examination.

Material and Methods

Farm management

The farm was located in Hordaland-county in Western Norway. During the 1960's and 1970's the livestock on the farm consisted of dairy goats, sheep and cattle, and in the summer seasons goats and cows grazed together on mountain pastures. In 1975, when paratuberculosis was first diagnosed in a goat on the farm, the herd consisted of 127 goats, 3 sheep and 8 cows. During the period 1975-1985, several goats showed clinical signs of paratuberculosis, and *M. a. paratuberculosis* was isolated from 31 goats. The cows in the herd were never examined for the infection, and no clinical data

are available for these animals during this period. The production of goat milk was terminated in 1992. From 1990-92, the farming gradually came to be exclusively dairy cattle production, and some cows were purchased from other farms. The herd followed typical Norwegian husbandry practices, combining both milk and meat production. During the winter seasons (October to May), all the animals were kept indoors. The milking cows and the heifers were kept in separate stalls, the fattening bulls and 2-3 month old calves were kept together in pens, while the youngest calves were kept in small pens or tied to the walls in the cow shed. However, according to observations made by a veterinarian, the small calves were also able to move freely around in the cow shed, suckling their mothers and other dairy cows. During the period from June to September, the cattle were kept on mountain pastures. Occasionally the animals had contact with cattle from other herds, but there were no sheep or goats on these pastures. Wild ruminants such as deer and moose were common on the mountain pastures.

The dairy cows in the herd were in good health and had an average milk and meat production. No clinical signs of paratuberculosis were noted in any animals at the time of culling.

Serological examinations

Serological examination was performed on 45 animals. The serum samples were tested with a commercial enzyme-linked immunosorbent assay (ELISA) for antibodies against *M. a. paratuberculosis* (Herd Chek™ IDEXX, Österbybruk, Sweden). The initial testing was performed in a single well, and all samples with S/P (sample to positive) ratios ≥ 0.1 were retested in duplicate. The results were classified as positive with S/P ratio ≥ 0.3 , doubtful with S/P ratio < 0.3 and ≥ 0.15 , and negative with S/P ratio < 0.15 .

Interferon gamma immunoassay

IFN- γ immunoassay was performed on 41 animals. Whole blood was cultured in 1 ml volumes in 24-well tissue culture trays with or without 10 $\mu\text{g/ml}$ purified protein derivative from *M. a. paratuberculosis* (PPDp) (National Veterinary Institute, Oslo, Norway). The samples were cultured for 24 h at 37°C in humidified air with 5% CO₂. Plasma supernatants were harvested and stored at -70°C until assayed. IFN- γ released into the plasma supernatants was measured in duplicate by using a sandwich ELISA for bovine IFN- γ (CSL, Victoria, Australia), according to the manufacturer's instructions. The results were expressed as OD 450 nm values in PPDp stimulated wells minus OD values in control wells. OD values ≥ 0.4 were classified as positive, OD values < 0.4 and ≥ 0.1 as weakly positive, while OD values below < 0.1 were classified as negative.

Pathological examinations

A full post-mortem examination was performed on 2 animals in September 1998. The animals were euthanised with intravenous pentobarbital and the post-mortem examination was performed immediately. Tissues from various organs were collected for histopathological examination, including several sections from the mid and distal jejunum, the ileum and the ileocecal valve, and from several mesenteric lymph nodes.

The rest of the herd (43 animals) was sent to slaughter (3 in October 1998 and 40 in June 1999), and a pathological examination was performed on organs sampled by a pathologist at the abattoir. The following material was collected for histopathology from each animal at the abattoir; samples from the mid-jejunum, distal jejunum, ileum, ileocecal valve, proximal colon, a jejunal lymph node and the cecal lymph node. Tissues were fixed in 10% neutral, buffered formalin, and processed by routine

paraffin embedding. Sections of 2-3 µm were cut, mounted and stained with haematoxylin-eosin (HE), and Ziehl-Neelsen (ZN) method was performed for detection of acid-fast bacilli. One HE and 1 ZN stained slide from each of the 7 formalin-fixed organ samples were examined initially. New sections of the formalin-fixed organ samples were processed and examined histologically from 21 of the 43 animals, in addition to serial sections of undeterminable granulomatous lesions in several animals.

Bacteriological examinations

Bacteriological examination was performed on faecal samples, and on samples from the ileocecal valve, and the mesenteric lymph nodes from all 45 animals in the herd. The samples were decontaminated with 4% sodium hydroxide and 5% oxalic acid with 0.1% malachite green, and inoculated onto selective and non-selective Dubos medium with mycobactin (2 µg/ml) and pyruvate (4 mg/ml) (Saxegaard 1985). Incubation time was 16 weeks at 37°C. Colonial morphology, mycobactin dependency, detection of acid fast rods with ZN staining and presence of the insertion segment IS900 (Sigurðardóttir et al. 1999) were used to identify the isolates.

Genotyping of isolates from goats and cattle

One single cattle isolate, confirmed as *M. a. paratuberculosis*, and 1 strain isolated from a goat on the same farm in 1985, were analysed by RFLP as described by Pavlik et al. (1999). Briefly, DNA was extracted from the isolates with lysozyme, sodium dodecyl sulfate and proteinase K, purified from the solution by chloroform:isoamylalcohol extraction and precipitated with isopropylalcohol. The DNA was digested by restriction endonucleases *Pst*I and *Bst*EI and hybridised with a standard PCR generated IS900 probe. The DNA fingerprints were

analysed and the types were designated as described by Pavlik et al. (1999).

Results

Results from the serological examinations, the IFN-γ immunoassay and the bacteriological and pathological examinations are presented in Table 1, while the ELISA OD values for IFN-γ and antibody response for animals in the different age groups are shown in Figure 1. Histopathological lesions compatible with paratuberculosis were diagnosed in 4 animals and confirmed by bacteriological isolation in 2 of these, animals that were 5 and 9 years old, respectively.

IFN-γ immunoassay and serological examinations

Nine animals gave positive results and 13 were weakly positive in the IFN-γ immunoassay, while 19 animals gave negative results in the test. Ten animals showed positive reactions in the serological test, and 5 were doubtful, while 30 animals gave negative reactions (Table 1). Three of the 4 animals of which paratuberculosis was verified by bacteriology and/or histopathology had a positive seroreaction, while only the youngest of these animals had a positive reaction in the IFN-γ immunoassay. Among the 41 animals in which paratuberculosis was not verified, 2 animals (4 years and 1 year old) showed both positive seroreaction and IFN-γ reaction. Two other animals (both 5 years old) had a positive seroreaction and a weak IFN-γ reaction, while 2 animals (4 years and 2.5 years old) showed a positive seroreaction and a negative IFN-γ reaction. Among the 30 seronegative animals, 5 were positive in the IFN-γ immunoassay. These animals were 1 year, 1.5 years, 1.5 years, 4 years, and 4 years old, respectively. The remaining 25 seronegative animals tested either doubtful or negative in the IFN-γ immunoassay.

Table 1. Results from interferon gamma immunoassays (IFN- γ), and serological, pathological and bacteriological examination of 45 animals in a dairy herd

Age (Years)	IFN γ ¹	Serology ²	Pathology ³	Bacteriology faeces/organs	No of animals
9	+	-	-	- / -	1
	nd	++	Granulomatous enteritis Acid fast rods	<i>M. a. paratuberculosis</i> / <i>M. a. paratuberculosis</i>	1 ⁴
	nd	++	-	- / -	1 ⁴
5	+	++	-	- / -	2
	-	++	Granulomatous enteritis Acid fast rods	- / -	1
	-	+/-	-	- / -	1
	-	-	Granulomatous enteritis Acid fast rods	- / <i>M. a. paratuberculosis</i>	1
	nd	-	-	- / -	1
4	++	++	Granulomatous enteritis Acid fast rods	<i>Mycobacterium</i> sp / -	1
	++	++	-	- / -	1
	++	-	-	- / -	2
	+	-	-	- / -	1
	-	++	-	- / -	1
	-	-	-	- / -	2
3	-	-	-	- / -	1
	nd	-	-	- / -	1
2.5	++	+/-	-	- / -	1
	+	+/-	-	- / -	1
	+	-	-	- / -	2
	-	++	-	- / -	1
	-	-	-	- / -	1
1.5	++	+/-	-	- / -	1
	++	-	-	<i>Mycobacterium</i> sp / -	1
	++	-	-	- / -	1
	+	-	-	- / -	1
	-	-	-	- / -	1
1.0	++	++	-	- / -	1
	++	-	-	- / -	1
	+	-	-	- / -	2
	-	+/-	-	- / -	1
	-	-	-	- / -	4
0.5	+	-	-	- / -	2
	-	-	-	- / -	4

¹ IFN- γ Positive (++): OD \geq 0.4; Weakly positive (+): OD \geq 0.1 and <0.4; Negative (-): OD<0.1.² ELISA Positive (++): S/P \geq 0.3; Doubtful (+/-): S/P \geq 0.15 and <0.3; Negative (-): S/P<0.15.³ Granulomatous enteritis without identification of acid-fast rods was considered a negative finding having aetiology other than infection with *Mycobacterium avium* subsp. *paratuberculosis*. Occasional small inflammatory foci without identification of acid-fast rods were seen. In over 50% of these lesions, the inflammatory cells contained pigment or foreign material such as coccidia and plant material.⁴ Animals that underwent full post-mortem examination.

nd = Not done

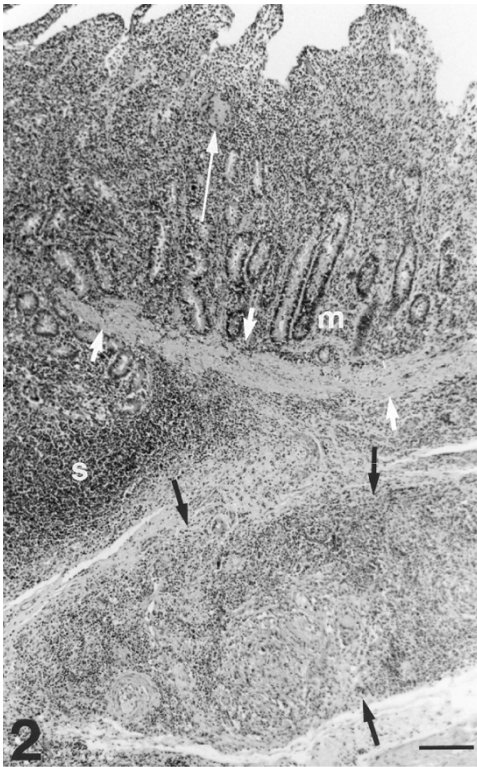


Fig. 2. Jejunum; cow, 9-years-old. Nodular, non-encapsulated, granulomatous inflammation in the submucosa (black arrows) and a single multinucleated giant cell (long white arrow) in the lamina propria mucosae. Acid-fast bacilli were demonstrated in ZN stained section of the lesion. m = mucosa, s = submucosa, short white arrows = lamina muscularis mucosae. HE. Bar = 160 μ m.

animals. The most severe lesions were found in the jejunum and ileum of the oldest cow. These lesions were characterised by multiple nodular, non-encapsulated, granulomatous inflammatory foci in the submucosa, lamina muscularis and in the serosa (Fig. 2). Many lymphatic vessels were surrounded by inflammatory cells, which were dominated by large, often foamy macrophages. There were moderate numbers of multinucleated giant cells (MNGC) and a few

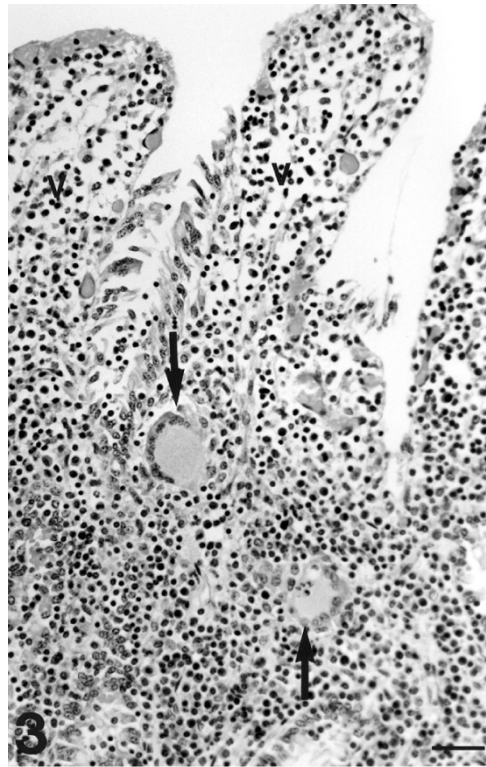


Fig. 3. Ileum; cow, 9-years-old. Two multinucleated giant cells (arrows) singly in the lamina propria mucosae. Most of the epithelium lining the villi (v) is missing. HE. Bar = 40 μ m.

eosinophilic leucocytes. In the lamina propria, there were moderate numbers of macrophages and MNGC. These cells were often present as single cells between the crypts and especially in the lamina propria of villi (Fig. 3). There were MNGC, either singly or in small clusters, in the cortex of jejunal lymph nodes. Acid-fast bacilli were detected within MNGC and macrophages in ZN stained sections of the intestine and lymph nodes. Lesions in the other 3 positive animals were very moderate and consisted of scattered small foci of inflammation, primarily in the lamina propria of villi. These lesions con-

tained MNGC, singly or a few together, and/or small clusters of large macrophages. In some of these lesions, a few acid-fast bacilli were detected in ZN stained sections. Two animals had lesions in the jejunum, whereas 1 had lesions in the ileum and in the ileocecal valve. Occasional small inflammatory foci, consisting of 1 or a few MNGC and a few macrophages, were seen within the intestinal wall of 19 animals. These lesions were found primarily in the mucosa of the jejunum and the ileocecal valve. In more than half of these lesions, the inflammatory cells contained pigment or foreign bodies such as plant material and coccidia.

Bacteriological examinations

M. a. paratuberculosis was isolated from 2 animals. The bacteria were cultured from faeces, lymph nodes and intestine of the oldest animal, and from only the intestine of the other animal (Table 1). Only 1 to 10 colony-forming units were found from each of the culture positive samples. A mycobacterium was detected in the faeces of 2 animals; one with histopathological lesions confirmed in the distal part of the jejunum and 1 young animal without pathological lesions. Only 1 colony-forming unit was detected in each sample, and due to growth failure these strains could not be identified. No mycobacteria were isolated from the remaining animal with histopathological lesions in the distal jejunum.

Genotyping of isolates from goats and cattle

Both the cattle strain and the goat strain belonged to RFLP type B-C1.

Discussion

The present study used a battery of diagnostic tests to confirm that the herd was infected with *M. a. paratuberculosis*. The sensitivity and specificity of the diagnostic tests depend among other factors on the prevalence of the infection

with *M. a. paratuberculosis* within the herd, and will thus give different results from herd to herd. However, in a herd that has been infected for many years, it is usual that at least 1 animal will show clinical signs. The infection in such an animal is usually quite easily confirmed by faecal culture and serology. About 25% of the remaining clinically healthy animals in the herd will be infected, but only ¼ of these will be detected by faecal culture (Whitlock & Buergelt 1996). In the present herd, no animals showed clinical signs of paratuberculosis, but 1 animal was found to shed bacteria in the faeces. Therefore, in this herd of 45 animals, the prediction would be that about 11 (25%) of the animals were infected. Serology and the IFN- γ assay detected 17 positive and 11 weakly positive/doubtful animals in either one or both of the tests, indicating that more than half of the herd was infected. This finding is consistent with a cattle herd heavily infected with *M. a. paratuberculosis*, although clinical signs would have been expected particularly in the 9 animals that were 5 years or older.

In general, the diagnostic results of the immunological tests showed a weak trend towards younger animals having raised IFN- γ tests and older animals having raised serological tests. There were however exceptions, and this limited the ability to state categorically that one test should be used in young animals and another in older animals. A raise in the cell mediated immunity (CMI) response in young animals and in the antibodies in older animals has been a common finding in many paratuberculosis studies. Experimental trials carried out in cattle showed that the CMI response can be detected shortly after the infection (McDonald et al. 1999), and the high proportion of CMI reactors observed during the first 2 years of life indicated that the majority of individuals become infected during this period. Investigations in sheep and goats have shown a relationship be-

tween pathological findings and the CMI response (Perez *et al.* 1999, Storset *et al.* 2001), and it has been suggested that the CMI response gives protection against the development of diffuse lesions. Our results indicate that a CMI response persisted in the animals for several years following infection, which possibly explains the limited clinical problems in the herd. Production of antibodies is often correlated with progression of the infection (Dargatz *et al.* 2001, Gasteiner *et al.* 2000), and in our study, 3 of the 4 cows with histopathological lesions had high levels of antibodies.

In the present study, pathological and bacteriological examinations detected the infection in 4 animals. A few other animals had small granulomatous inflammatory lesions in the intestine devoid of demonstrable acid-fast bacilli or foreign material and could therefore have been due to *M. a. paratuberculosis* infection. This type of lesion was however no more frequent in seropositive than in seronegative animals, and many seropositive animals had no histopathological lesion indicative of paratuberculosis. More exhaustive tissue sampling for both histopathology and bacteriology may have confirmed infection in additional animals, since discrete subclinical lesions can be widely distributed throughout the intestinal tract and mesenteric lymph nodes (Whitlock *et al.* 1996). The 4 confirmed positive animals were all older than 4-5 years. In animals up to 4 years of age the IFN- γ immunoassay would appear to be the relevant screening test, while a test measuring antibodies would be preferable in animals from 3 years and older. In cattle, however, the age of the animals can have an impact on the IFN- γ results. False positive reactions have been observed when the IFN- γ test has been applied to calves less than 15 months of age (Jungersen *et al.* 2002, Olsen & Storset 2001). Furthermore, cross-reactions with other mycobacteria are common (Griffin *et al.* 1991, McDonald *et al.*

1999), reducing the specificity of both serological and IFN- γ assays. These cross-reacting mycobacteria are common in the environment (Tell *et al.* 2001), and could well have caused some of the immunoreactions in the animals in the present study. Results from the Norwegian surveillance and control programme for paratuberculosis (Djønne *et al.* 2001a), have shown that about 8% of Norwegian cattle are seroreactors. A follow-up study of these seropositive cattle has shown that the reactions were false positive, and were probably caused by environmental mycobacteria (Fredriksen *et al.* 2004). The clinical problems with paratuberculosis in cattle in Norway have been insignificant compared with those in goats during the second half of the last century, and there has been uncertainty whether the *M. a. paratuberculosis* strains in goats in Norway are pathogenic in cattle (Saxegaard 1990). However, several observations indicate that strains isolated from one animal species can infect other species (Friðriksdóttir *et al.* 2000, Kennedy & Allworth 2000, Muskens *et al.* 2001, Whittington *et al.* 2001), and that strains isolated from one animal species and orally administered to another species have led to infection (Beard *et al.* 2001, Dukes *et al.* 1992, Williams *et al.* 1983). Paratuberculosis had been a clinical problem in goats on the present farm several years before the present study was conducted, and the infection might well have existed in cattle in a subclinical form. The same RFLP patterns were found in the *M. a. paratuberculosis* strain isolated from cattle in our study as in a strain isolated from a goat on the farm several years previously. This RFLP pattern is the predominant type in Norwegian goats (Djønne, unpublished observations) and in cattle from Europe and the United States (Pavlik *et al.* 2000, Whipple *et al.* 1990). These findings indicate that the same *M. a. paratuberculosis* strain has infected goats and cattle.

Our observations do not exclude that the present strain shows different pathogenicity for cattle and goats, but there are factors other than animal species that should be considered when evaluating the pathogenicity of *M. a. paratuberculosis* for cattle and goats. These factors include management conditions and breed resistance. The management conditions are quite different for cattle and goats in Norway. The cattle units are small, the young calves are usually separated from their dams shortly after birth, animals older than 1 year are usually housed in separate stalls, and the average age of the cows is low (3.9 years of age). All of these management factors have been shown to reduce the spread of infection in a herd (Johnson-Iffearulundu & Kaneene 1998, Obasanjo et al. 1997, Rossiter & Burhans 1996). The goat kids, however, are often born in pens where several goats are housed. Thus, one single offspring might suckle several dams, and the risk of infection with faecal material from a bacterial shedder should therefore be higher in goats than in cattle. In the present herd, in contrast to the general management condition described above, 9 cows were older than 4 years, and 3 of these were 9 years old. In addition, the young calves were allowed to move freely among adult cows, which might have exposed several individuals to contact with one single shedder.

Paratuberculosis was considered to be a clinical problem in the Norwegian cattle population during the first part of the 20th century. At that time, different local cattle breeds made up the cattle population in Norway. After 1970, the majority of the population was drawn from the Norwegian red cattle breed, which is a hybrid of many different breeds. In recent decades, paratuberculosis has been considered a minor problem in the cattle population in Norway, and clinical cases were not reported between 1979 and 2001. Thus one can speculate that the Norwegian red cattle breed is more resistant to clin-

ical infection with *M. a. paratuberculosis* than the local cattle breeds.

The present study shows that the infection might be subclinical in cattle herds, and may be overlooked if immunological, pathological and bacteriological investigations are not performed.

Acknowledgements

The authors thank Asle Johannes Bjørgaas, Per Lorentzen, Ola Skjelde and Magne Skjervheim for practical assistance during the collection of material in the herd, and Anneri Sundstrøm and Oddny Kleivane for technical help during the pathological examinations.

We also thank Grete Berntsen for technical work during the IFN- γ assay, Merete Rusaas Jensen, Nina Fundingsrud and Sigrun Nilsen for technical assistance during the bacteriological examinations, and Dr. Ivo Pavlik, Vet. Research Inst., Brno, Czech Republic, for doing the RFLP typing.

References

- Beard PM, Stevenson K, Pirie A, Rudge K, Buxton D, Rhind SM, Sinclair MC, Wildblood LA, Jones DG, Sharp JM: Experimental paratuberculosis in calves following inoculation with a rabbit isolate of *Mycobacterium avium* subsp. paratuberculosis. *J. Clin. Microbiol.* 2001, 39, 3080-3084.
- Chiodini RJ, Van Kruiningen HJ, Merkal RS: Ruminant paratuberculosis (Johne's disease): the current status and future prospects. *Cornell Vet.* 1984, 74, 218-262.
- Dargatz DA, Byrum BA, Barber LK, Sweeney RW, Whitlock RH, Shulaw WP, Jacobson RH, Stabel JR: Evaluation of a commercial ELISA for diagnosis of paratuberculosis in cattle. *J. Am. Vet. Med. Assoc.* 2001, 218, 1163-1166.
- Djønne B, Fredriksen B, Nyberg O, Sigurðardóttir ÓG, Tharaldsen J: National bovine paratuberculosis program in Norway. *Bull. Int. Dairy Fed.* 2001a, 364, 75-80.
- Djønne B, Nyberg O, Fredriksen B, Sigurðardóttir Ó, Tharaldsen J: The surveillance and control programme for paratuberculosis in Norway. Surveillance and control programmes for terrestrial and aquatic animals in Norway. Norwegian Animal Health Authority, National Veterinary Institute, Norwegian Food Control Authority. Annual Report 2001b.

- Dukes TW, Glover GJ, Brooks BW, Duncan JR, Swendrowski M: Paratuberculosis in saiga antelope (*Saiga tatarica*) and experimental transmission to domestic sheep. *J. Wildl. Dis.* 1992, 28, 161-170.
- Eamens GJ, Whittington RJ, Marsh IB, Turner MJ, Saunders V, Kemsley PD, Rayward D: Comparative sensitivity of various faecal culture methods and ELISA in dairy cattle herds with endemic Johne's disease. *Vet. Microbiol.* 2000, 77, 357-367.
- Fredriksen B, Djonne B, Sigurðardóttir Ó, Tharaldsen J, Nyberg O, Jarp J: Factors affecting the herd level of antibodies against *Mycobacterium avium* subspecies paratuberculosis in dairy cattle. *Vet Rec* 2004, 152, 522-526.
- Friðriksdóttir V, Gunnarsson E, Sigurðarson S, Guðmundsdóttir KB: Paratuberculosis in Iceland: epidemiology and control measures, past and present. *Vet. Microbiol.* 2000, 77, 263-267.
- Gasteiner J, Awad-Masalmeh M, Baumgartner W: *Mycobacterium avium* subsp. paratuberculosis infection in cattle in Austria, diagnosis with culture, PCR and ELISA. *Vet. Microbiol.* 2000, 77, 339-349.
- Griffin JF, Nagai S, Buchan GS: Tuberculosis in domesticated red deer: comparison of purified protein derivative and the specific protein MPB70 for in vitro diagnosis. *Res. Vet. Sci.* 1991, 50, 279-285.
- Jakobsen MB, Alban L, Nielsen SS: A cross-sectional study of paratuberculosis in 1155 Danish dairy cows. *Prev. Vet. Med.* 2000, 46, 15-27.
- Johnson-Ifearulundu YJ, Kaneene JB: Management-related risk factors for *M. paratuberculosis* infection in Michigan, USA, dairy herds. *Prev. Vet. Med.* 1998, 37, 41-54.
- Jubb T, Galvin J: Herd testing to control bovine Johne's disease. *Vet. Microbiol.* 2000, 77, 423-428.
- Jungersen G, Huda A, Hansen JJ, Lind P: Interpretation of the gamma interferon test for diagnosis of subclinical paratuberculosis in cattle. *Clin. Diagn. Lab. Immunol.* 2002, 9, 453-460.
- Kennedy DJ, Allworth MB: Progress in national control and assurance programs for bovine Johne's disease in Australia. *Vet. Microbiol.* 2000, 77, 443-451.
- McDonald WL, Ridge SE, Hope AF, Condon RJ: Evaluation of diagnostic tests for Johne's disease in young cattle. *Aust. Vet. J.* 1999, 77, 113-119.
- Muskens J, Bakker D, de Boer J, van Keulen L: Paratuberculosis in sheep: its possible role in the epidemiology of paratuberculosis in cattle. *Vet. Microbiol.* 2001, 78, 101-109.
- Nielsen SS, Gronbaek C, Agger JF, Houe H: Maximum-likelihood estimation of sensitivity and specificity of ELISAs and faecal culture for diagnosis of paratuberculosis. *Prev. Vet. Med.* 2002, 53, 191-204.
- Obasanjo IO, Grohn YT, Mohammed HO: Farm factors associated with the presence of *Mycobacterium paratuberculosis* infection in dairy herds on the New York State Paratuberculosis Control Program. *Prev. Vet. Med.* 1997, 32, 243-251.
- Olsen I, Sigurðardóttir ÓG, Djonne B: Paratuberculosis with special reference to cattle. A review. *Vet. Q.* 2002, 24, 12-28.
- Olsen I, Storset AK: Innate IFN-gamma production in cattle in response to MPP14, a secreted protein from *Mycobacterium avium* subsp. paratuberculosis. *Scand. J. Immunol.* 2001, 54, 306-313.
- Pavlik I, Bartl J, Dvorska L, Svastova P, du Maine R, Machackova M, Yayo Ayele W, Horvathova A: Epidemiology of paratuberculosis in wild ruminants studied by restriction fragment length polymorphism in the Czech Republic during the period 1995-1998. *Vet. Microbiol.* 2000, 77, 231-251.
- Pavlik I, Horvathova A, Dvorska L, Bartl M, Svastova P, du Maine R, Rychlik I: Standardisation of restriction fragment length polymorphism analysis for *Mycobacterium avium* subspecies paratuberculosis. *J. Microbiol. Methods.* 1999, 38, 155-167.
- Perez V, Tellechea J, Corpa JM, Gutierrez M, Garcia Marin JF: Relation between pathologic findings and cellular immune responses in sheep with naturally acquired paratuberculosis. *Am. J. Vet. Res.* 1999, 60, 123-127.
- Reichel MP, Kittelberger R, Penrose ME, Meynell RM, Cousins D, Ellis T, Mutharia LM, Sugden EA, Johns AH, de Lisle GW: Comparison of serological tests and faecal culture for the detection of *Mycobacterium avium* subsp. paratuberculosis infection in cattle and analysis of the antigens involved. *Vet. Microbiol.* 1999, 66, 135-150.
- Rossiter CA, Burhans WS: Farm-specific approach to paratuberculosis (Johne's disease) control. *Vet. Clin. North Am. Food Anim. Pract.* 1996, 12, 383-415.
- Saxegaard F: Experimental infection of calves with an apparently specific goat-pathogenic strain of *Mycobacterium paratuberculosis*. *J. Comp.*

- Pathol. 1990, 102, 149-156.
- Saxegaard F: Isolation of *Mycobacterium paratuberculosis* from intestinal mucosa and mesenteric lymph nodes of goats by use of selective Dubos medium. J. Clin. Microbiol. 1985, 22, 312-313.
- Sigurðardóttir ÓG, Press CMcL, Saxegaard F, Evensen Ø: Bacterial isolation, immunological response, and histopathological lesions during the early subclinical phase of experimental infection of goat kids with *Mycobacterium avium* subsp. *paratuberculosis*. Vet. Pathol. 1999, 36, 542-550.
- Storset AK, Hasvold HJ, Valheim M, Brun-Hansen H, Berntsen G, Whist SK, Djønne B, Press CMcL, Holstad G, Larsen HJS: Subclinical paratuberculosis in goats following experimental infection. An immunological and microbiological study. Vet. Immunol. Immunopathol. 2001, 80, 271-287.
- Tell LA, Woods L, Cromie RL: Mycobacteriosis in birds. Rev. Sci. Tech. 2001, 20, 180-203.
- Whipple D, Kapke P, Vary C: Identification of restriction fragment length polymorphisms in DNA from *Mycobacterium paratuberculosis*. J. Clin. Microbiol. 1990, 28, 2561-2564.
- Whitlock RH, Buergelt C: Preclinical and clinical manifestations of paratuberculosis (including pathology). Vet. Clin. North Am. Food Anim. Pract. 1996, 12, 345-356.
- Whitlock RH, Rosenberger AE, Sweeney RW, Spencer PA: Distribution of *M. paratuberculosis* in tissues of cattle from herds infected with Johne's disease. In: Proceedings of the 5th International Colloquium on Paratuberculosis, eds. Chiodini RJ, Hines ME, Collins MT, pp.168-174. International Association for Paratuberculosis, Inc., Madison, Wisconsin, USA. 1996.
- Whittington RJ, Sergeant ES: Progress towards understanding the spread, detection and control of *Mycobacterium avium* subsp. *paratuberculosis* in animal populations. Aust. Vet. J. 2001, 79, 267-278.
- Whittington RJ, Taragel CA, Ottaway S, Marsh I, Seaman J, Fridriksdóttir V: Molecular epidemiological confirmation and circumstances of occurrence of sheep (S) strains of *Mycobacterium avium* subsp. *paratuberculosis* in cases of paratuberculosis in cattle in Australia and sheep and cattle in Iceland. Vet. Microbiol. 2001, 79, 311-322.
- Williams ES, Snyder SP, Martin KL: Experimental infection of some North American wild ruminants and domestic sheep with *Mycobacterium paratuberculosis*: clinical and bacteriological findings. J. Wildl. Dis. 1983, 19, 185-191.

Sammendrag

Beskrivelse av infeksjonsstatus i en Norsk storfebesetning smittet med *Mycobacterium avium* subsp. *paratuberculosis*.

I regi av overvåkings- og kontrollprogrammet for paratuberkulose ble det oppdaget åtte seropositive dyr i en melkekubesetning uten klinisk sykdom. Klinisk paratuberkulose hadde vært et problem på geit noen år tidligere på den samme gården. Besetningen på 45 storfe ble slaktet og en grundig undersøkelse av infeksjonsstatus ble foretatt ved bruk av interferon- γ (IFN- γ) test, måling av antistoffnivå, samt patologisk og bakteriologisk undersøkelse. IFN- γ testen gav positivt resultat på 9 dyr, svakt positivt resultat på 13 dyr og negativt resultat på 19 dyr. Serologisk undersøkelse ga positivt resultat på 10 dyr, usikkert resultat på 5 dyr og negativt resultat på 30 dyr. Det var en svak tendens til forhøyet IFN- γ hos unge dyr og forhøyet antistoffnivå hos eldre dyr. Histopatologiske lesjoner forenlige med paratuberkulose ble påvist hos 4 dyr som var mellom 4 og 9 år. Tre av disse dyrene var positive på serologi og ett dyr ga også positivt resultat i IFN- γ testen. Infeksjonen ble bekreftet ved dyrking av *Mycobacterium avium* subsp. *paratuberculose* (*M. a. paratuberculosis*) fra 2 av disse 4 dyrene. Et bakterieisolat undersøkt ved hjelp av RFLP metoden hadde samme profil, B-C1, som en stamme isolert flere år tidligere fra en geit på denne gården. Til tross for at mange dyr var positive i en eller begge av disse immunologiske testene, et funn som antyder en gjennominfisert besetning, viste ingen av dyrene kliniske symptomer, og utskillelse av bakterier i feces ble påvist hos kun ett dyr. Kryssreaksjon med andre mykobakterier kan ha forårsaket noen av de immunologiske reaksjonene hos disse dyrene. Det er også mulig at NRF-rasen er motstandsdyktig mot klinisk *M. a. paratuberculosis* infeksjon.

(Received December 22, 2003; accepted February 22, 2005).

Reprints may be obtained from: Ólöf G. Sigurðardóttir, Lyfjaþróun Biopharmaceuticals, Vatnagarðar 16-18, 104 Reykjavík, Iceland. E-mail: loa@lyf.is, tel: +354 511 2020, fax: +354 511 2021.